

# CASE PRESENTATIONS

---

Laura C. Collins, M.D.

Vice Chair of Anatomic Pathology

Professor of Pathology

Beth Israel Deaconess Medical Center

and Harvard Medical School

Boston, MA

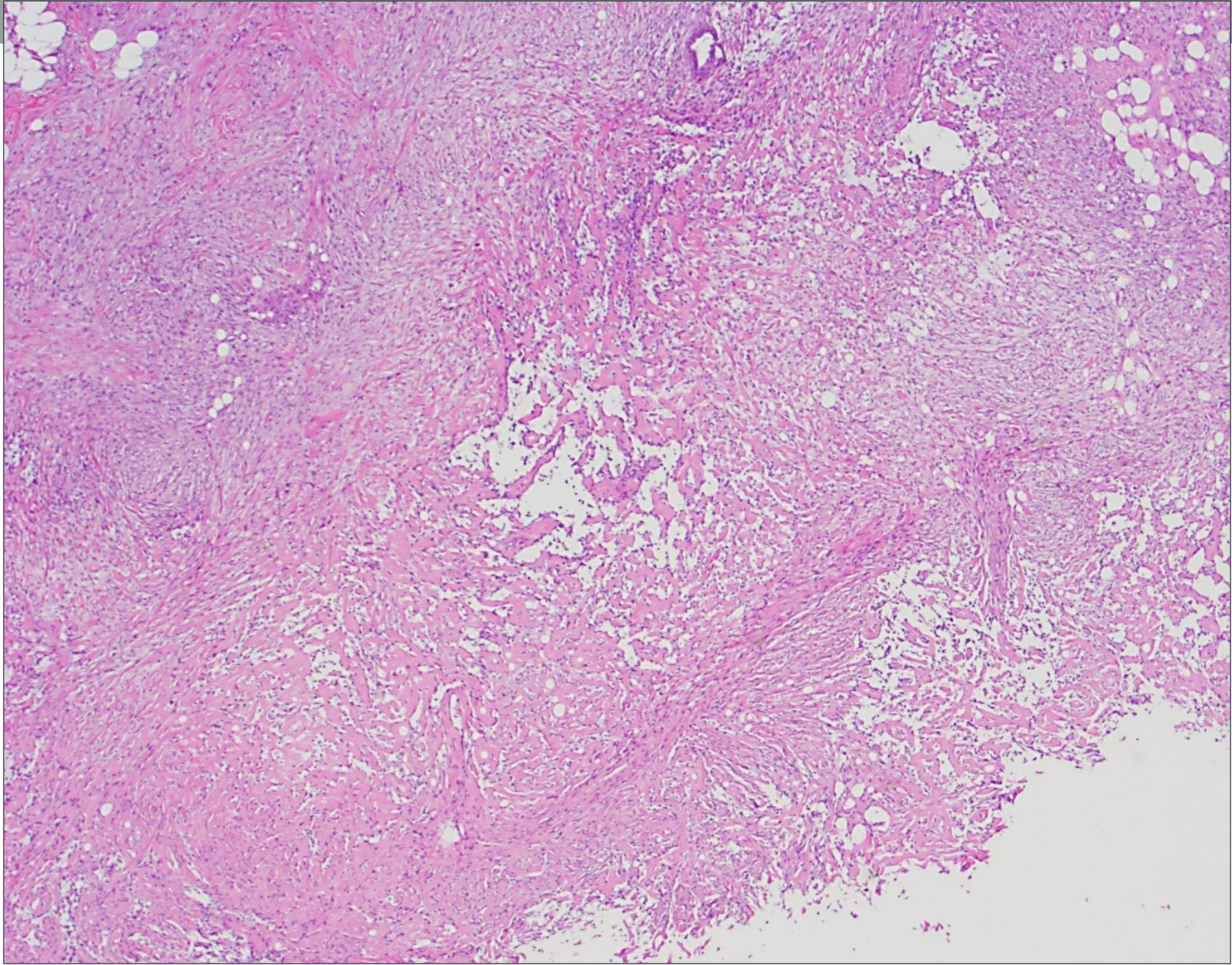
- I have no disclosures/COI

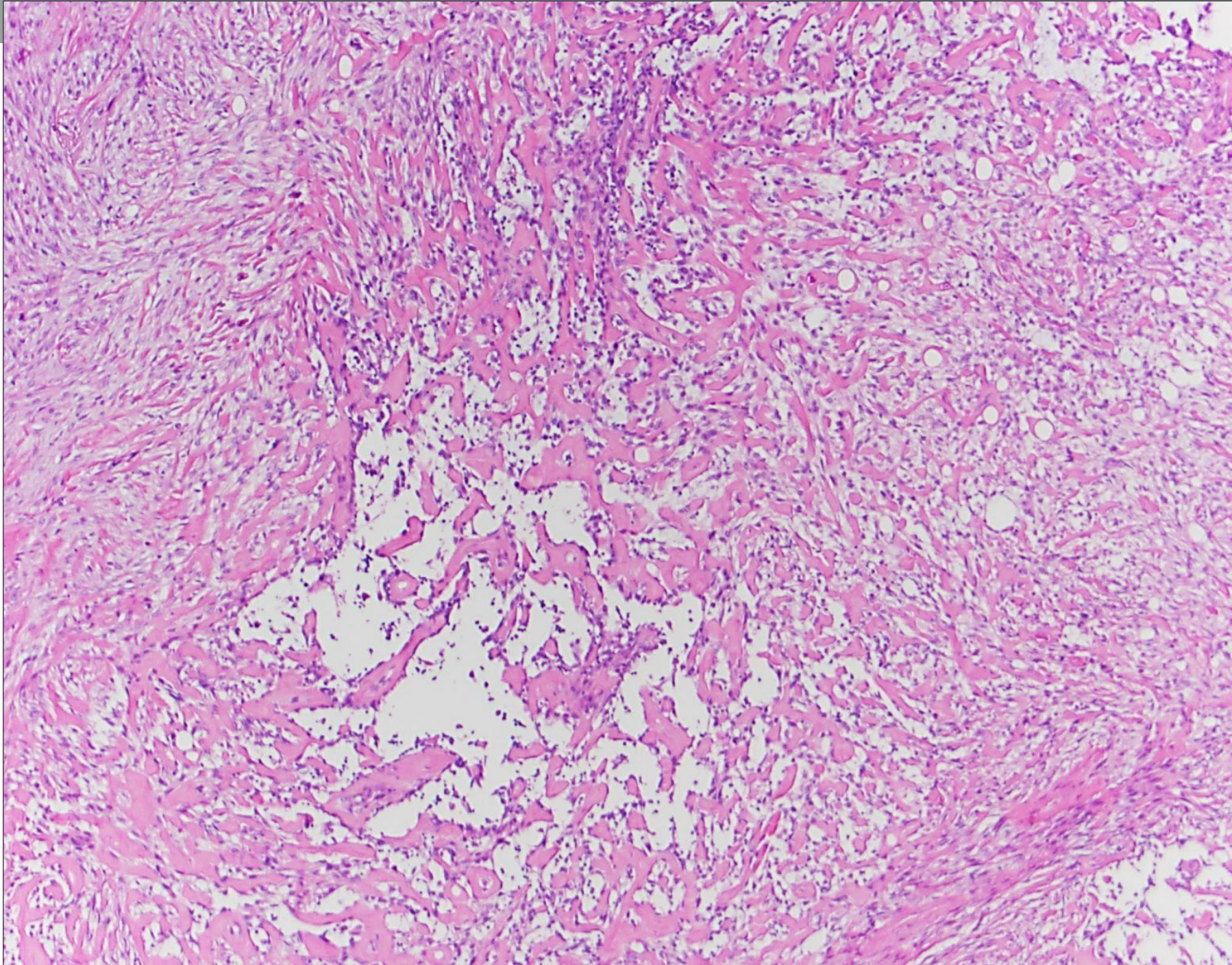
# CASE 1

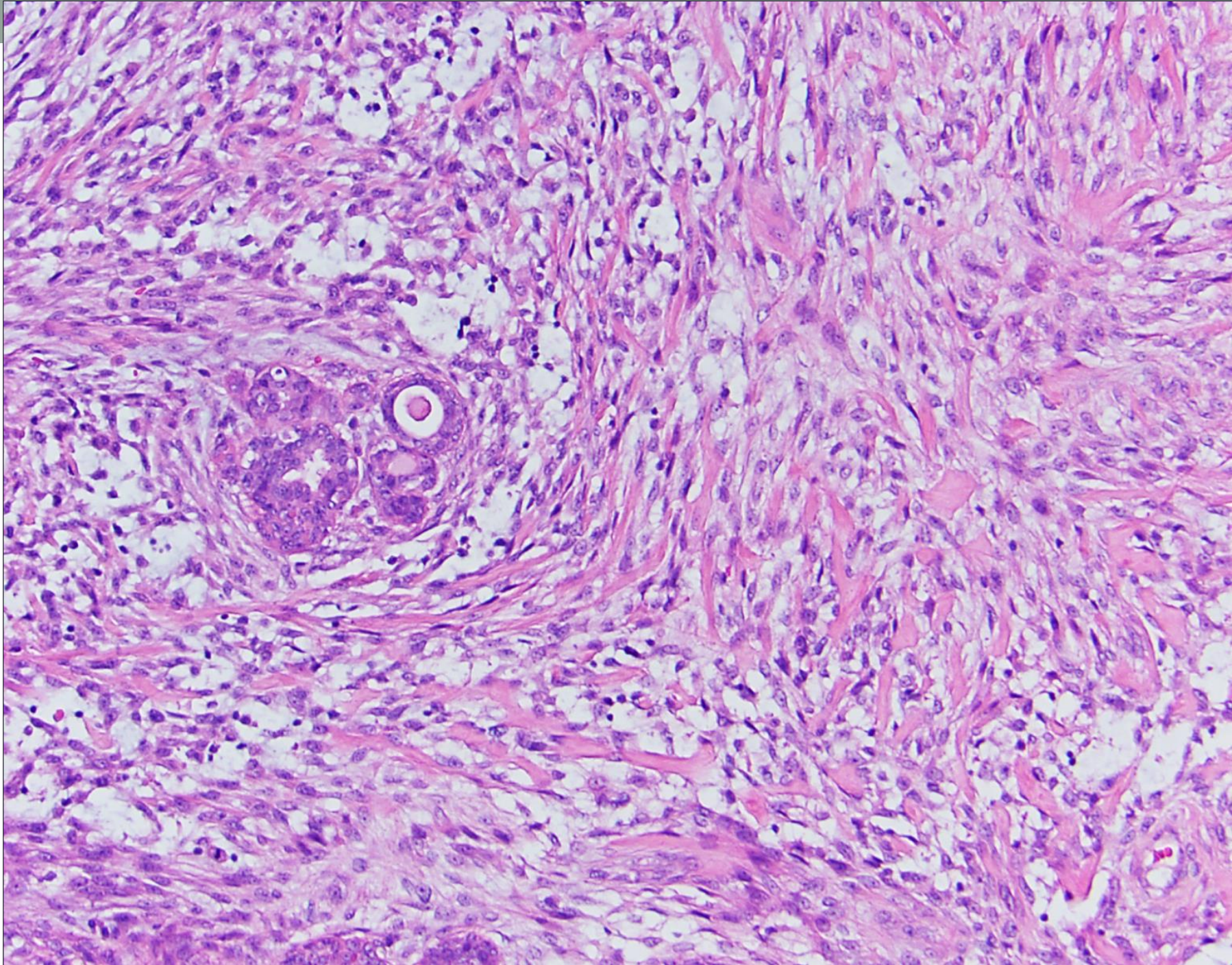
---

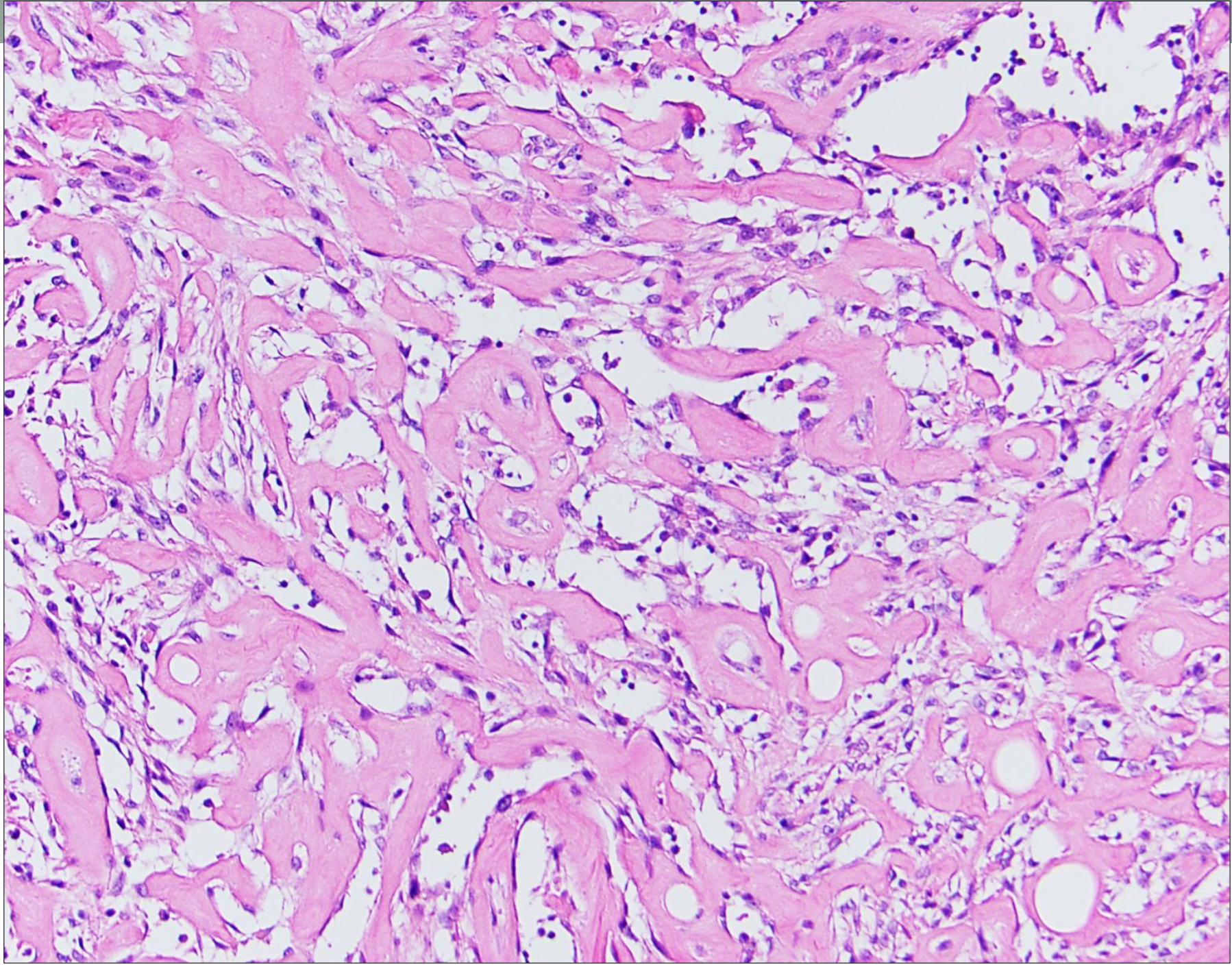
# Case 1

- 72 year old woman with a history of grade 2 invasive ductal carcinoma, ER low positive, HER2 negative, for which she was treated with lumpectomy and radiation therapy
- She completed treatment ~9 months earlier
- She presented with an image-detected mass at the site of her prior surgery
- ?recurrence vs. fat necrosis

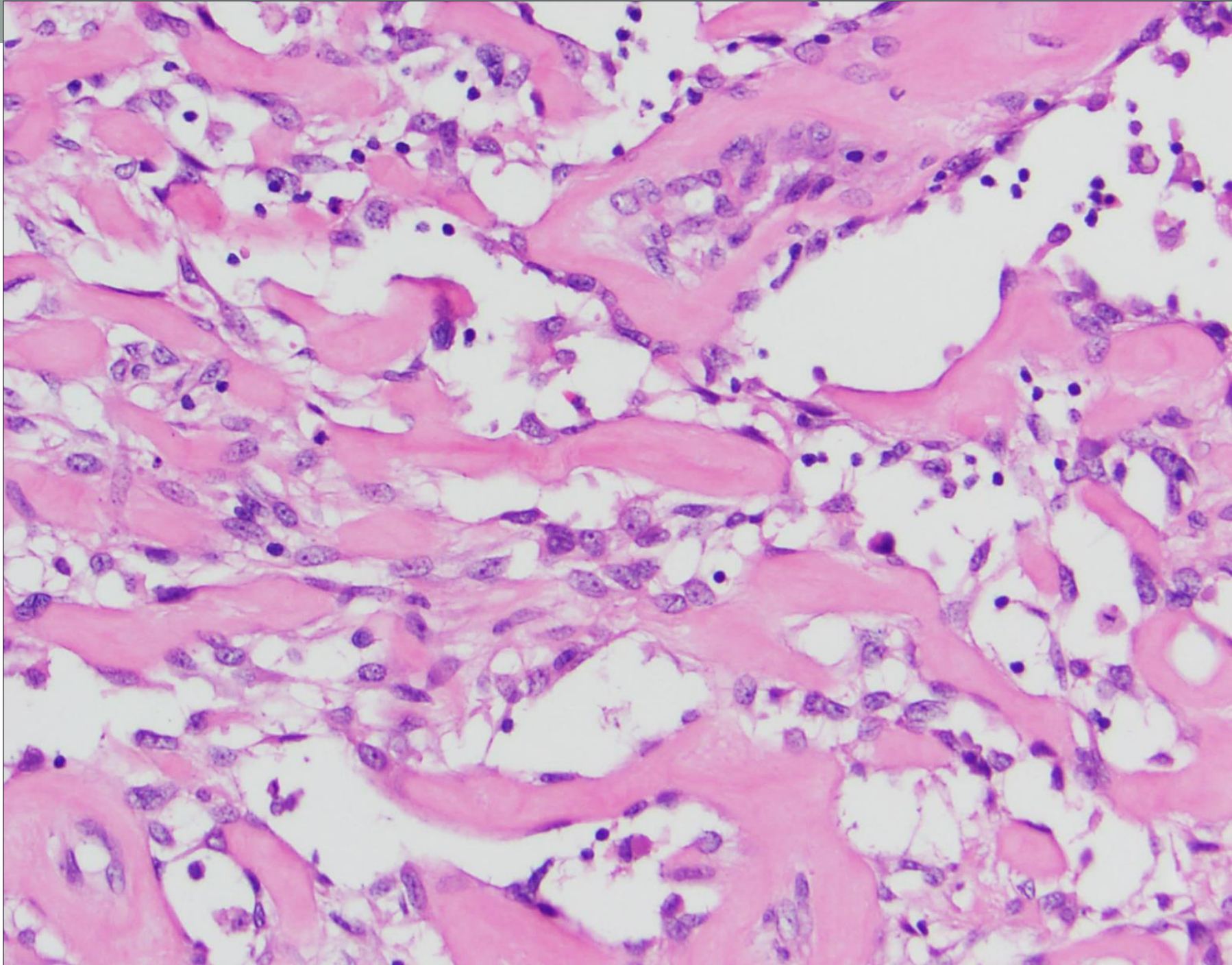


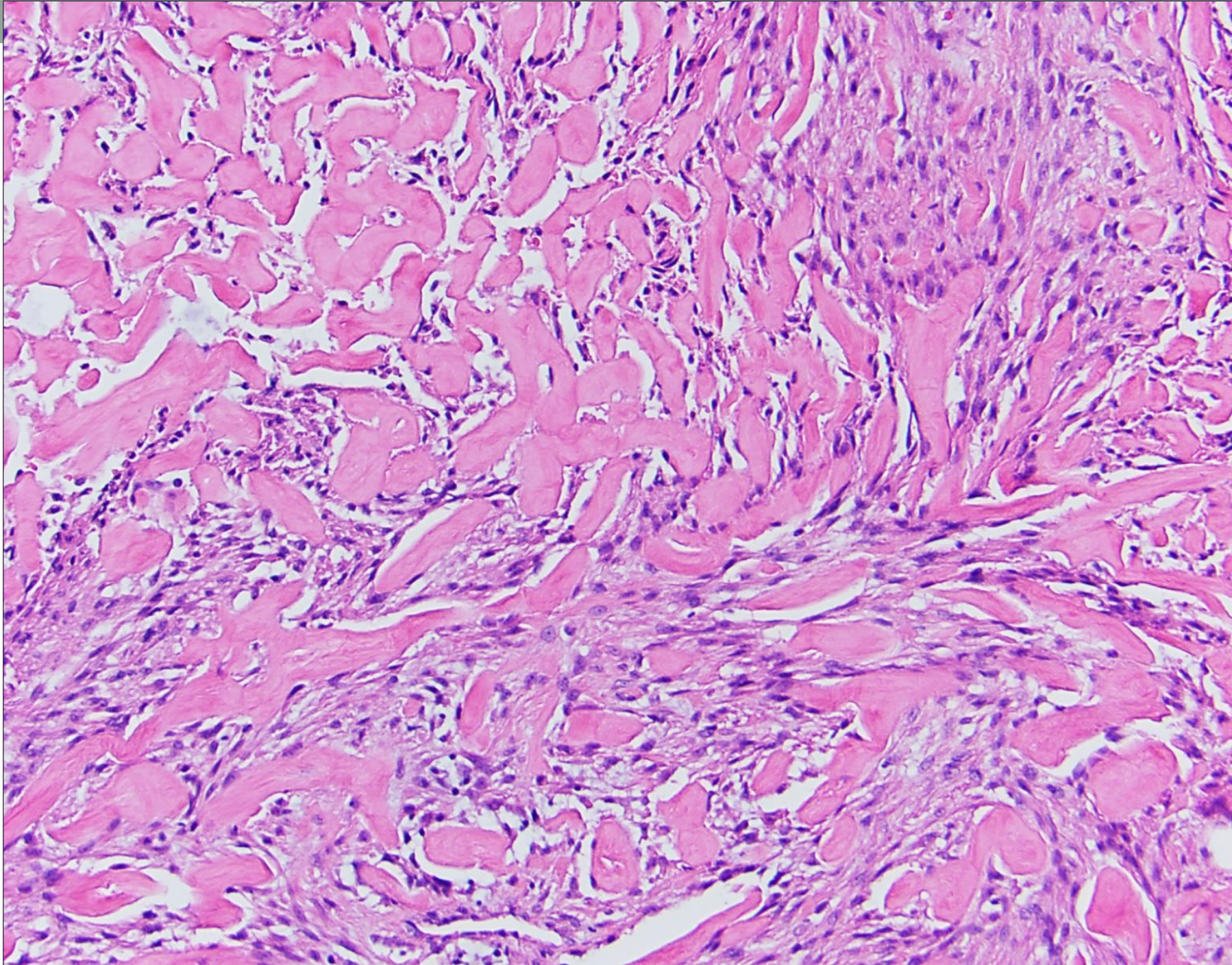


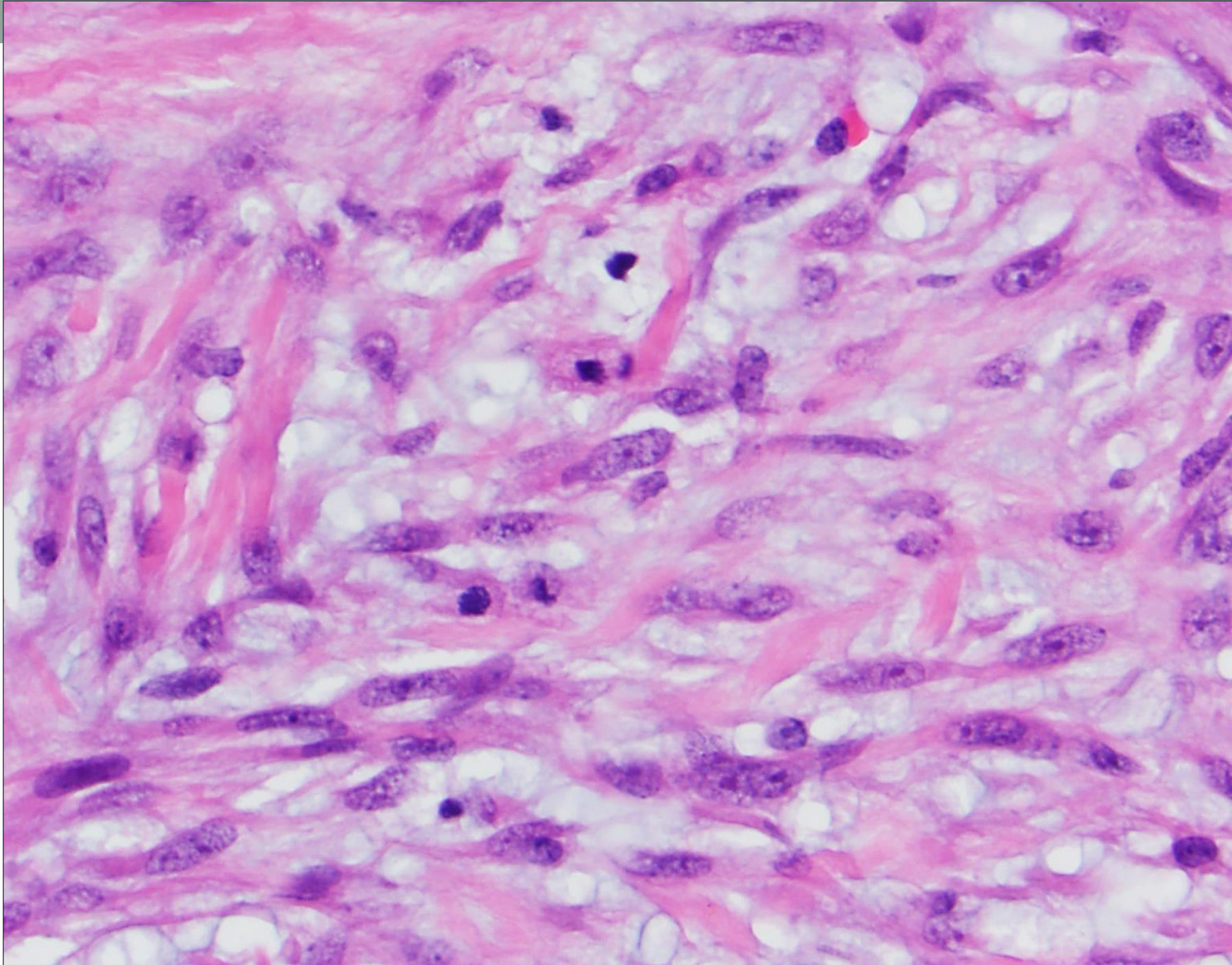












# DIAGNOSTIC CONSIDERATIONS?

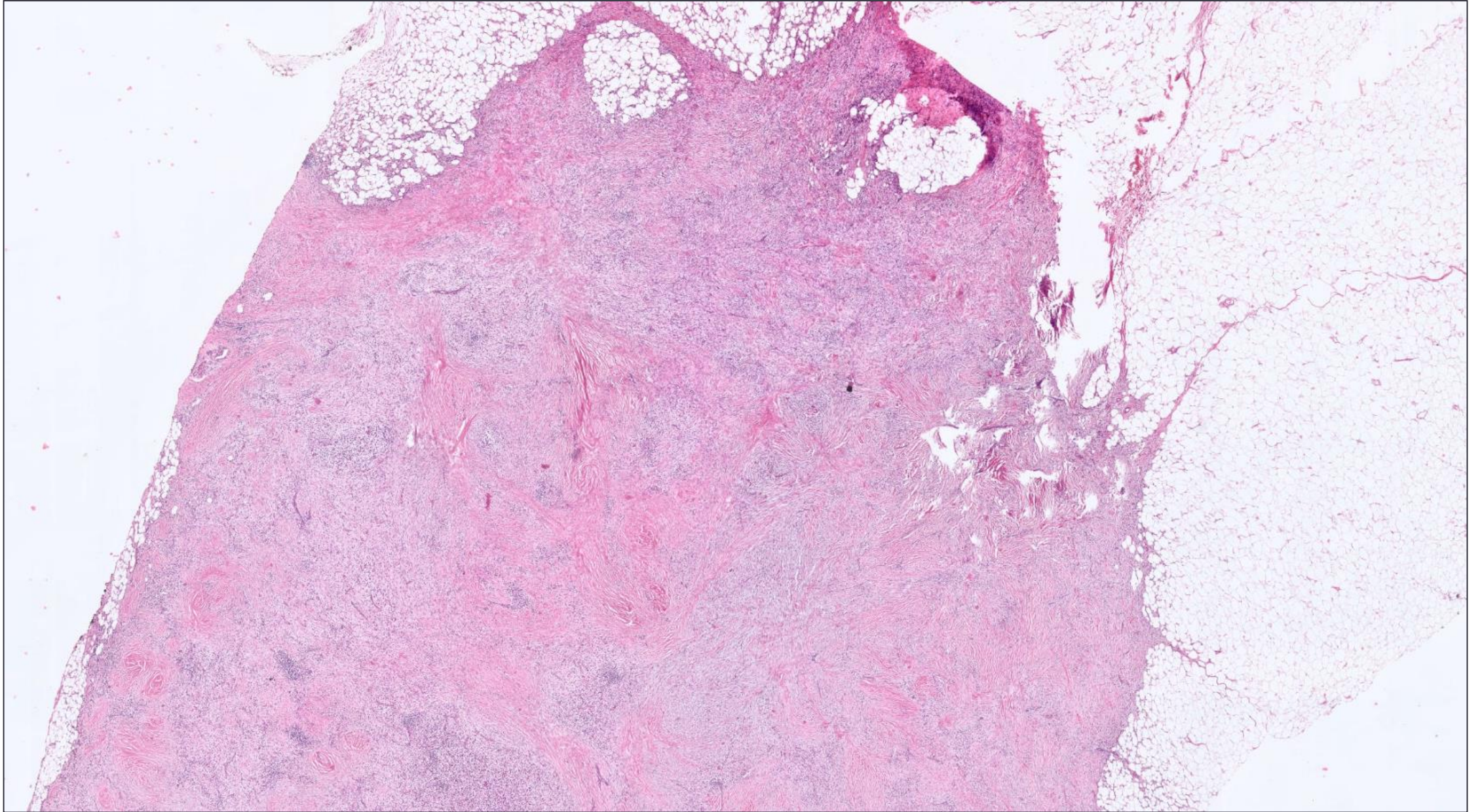
---

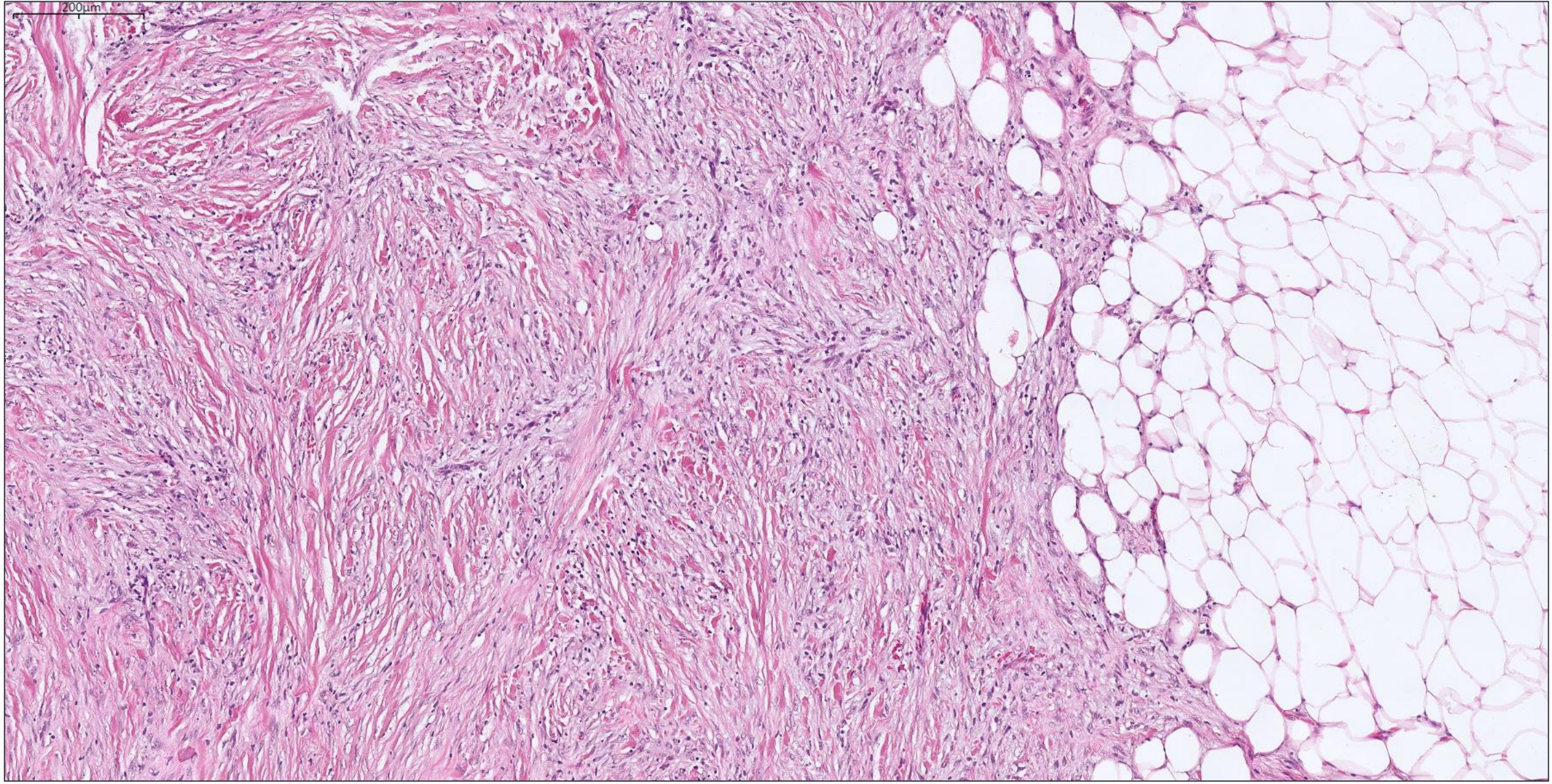
# CASE 2

---

## Case 2

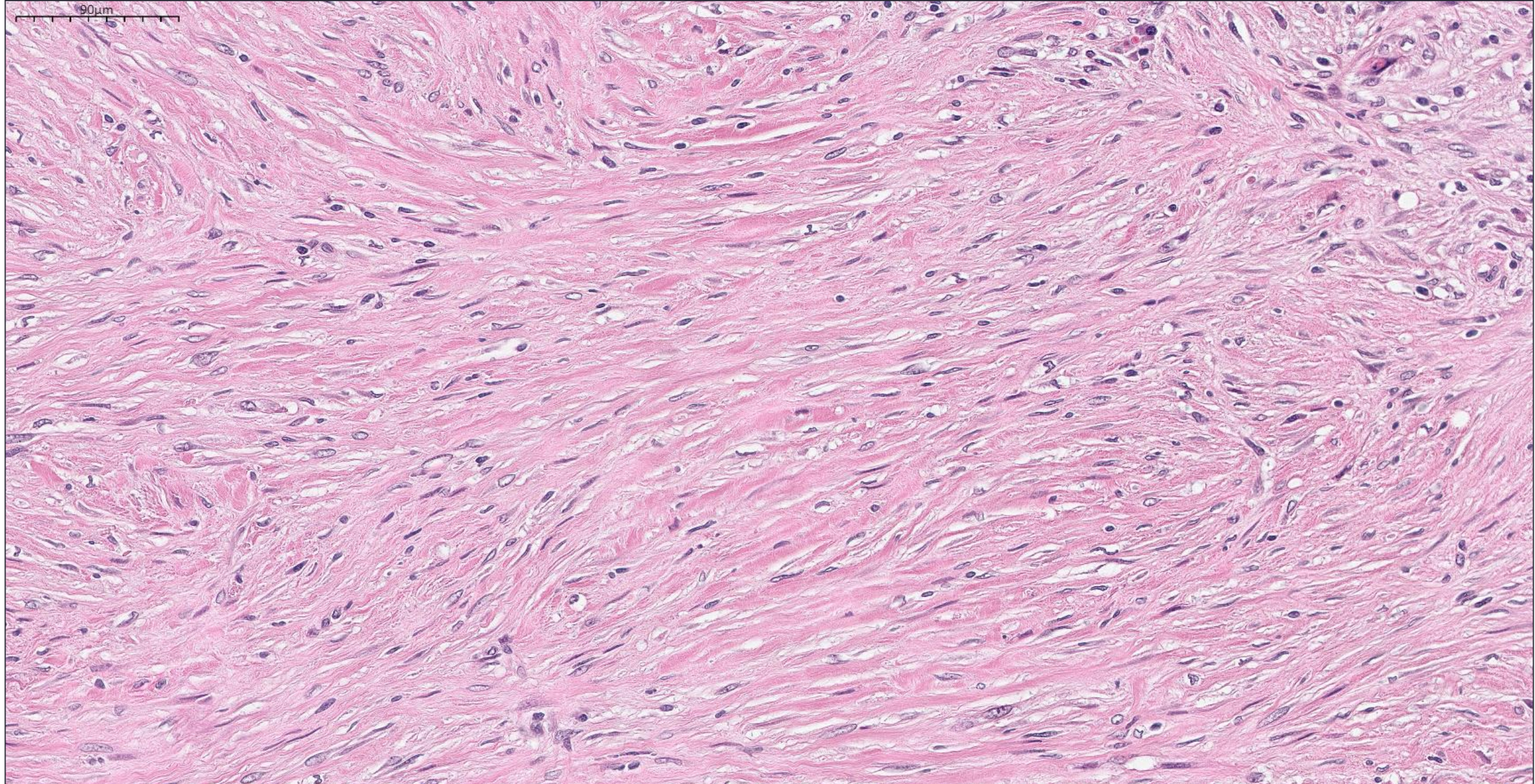
- 72 year old woman presented with a left breast mass, which she noticed following a recent car accident
- Airbag deployed







90µm

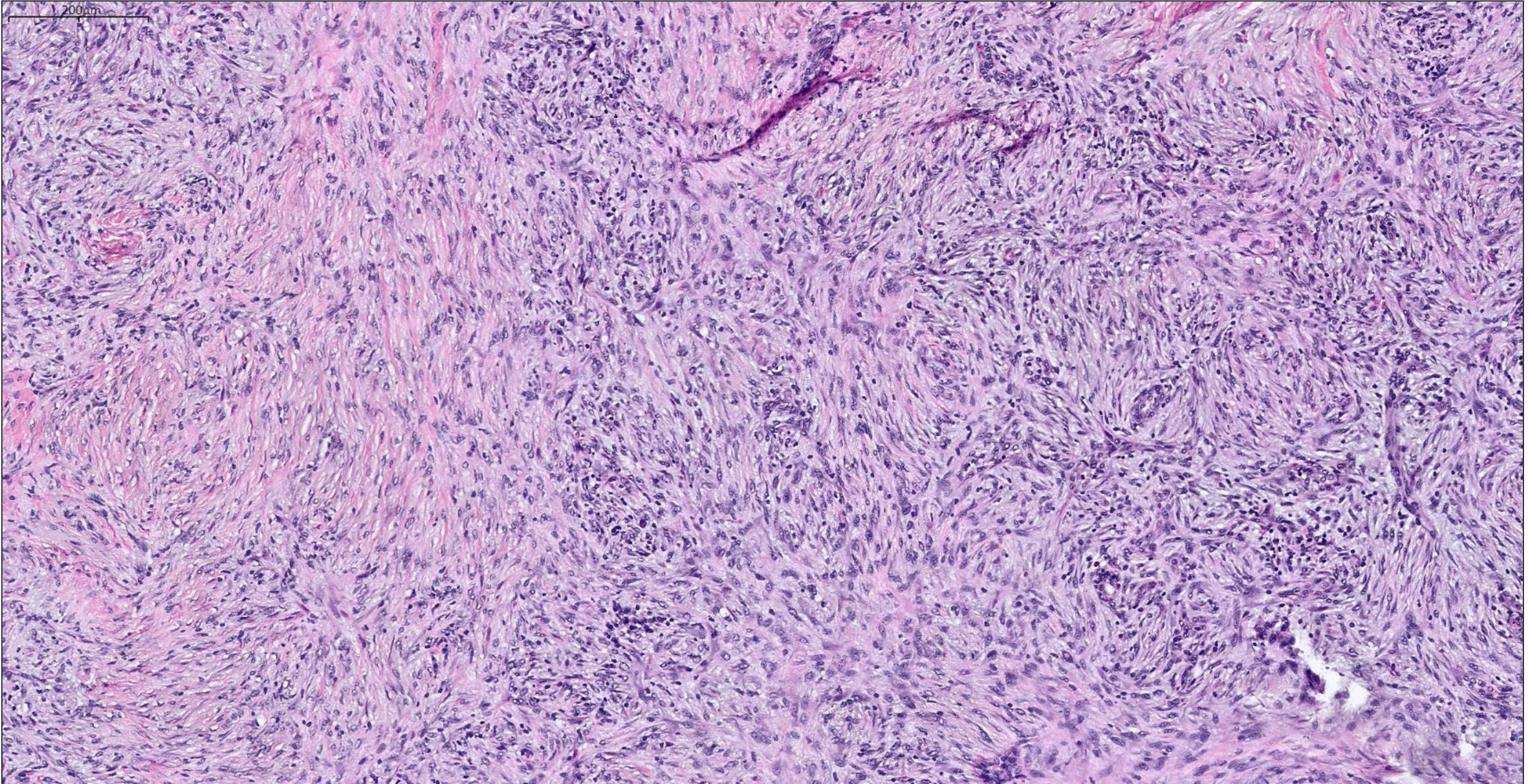


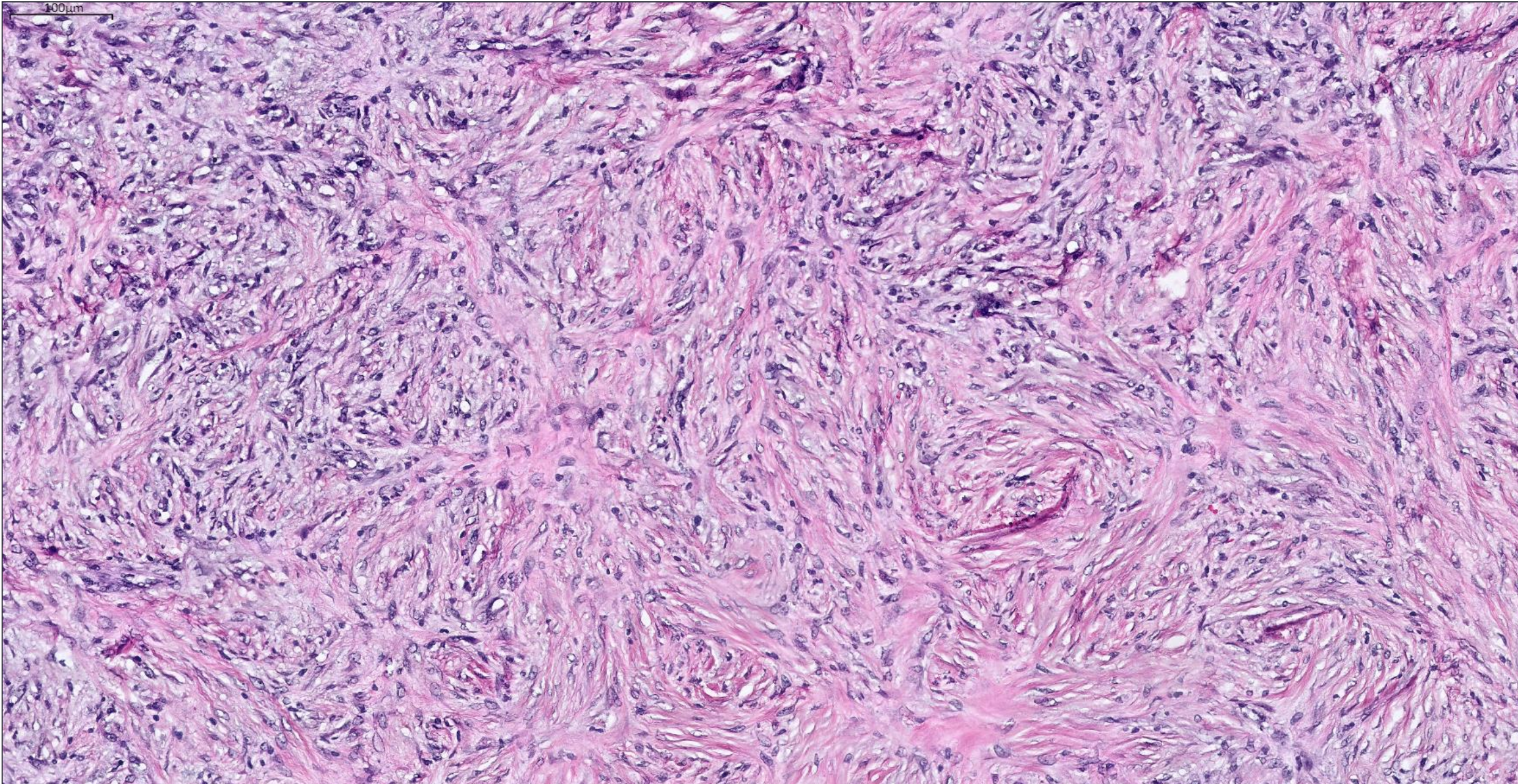
# DIAGNOSTIC CONSIDERATIONS?

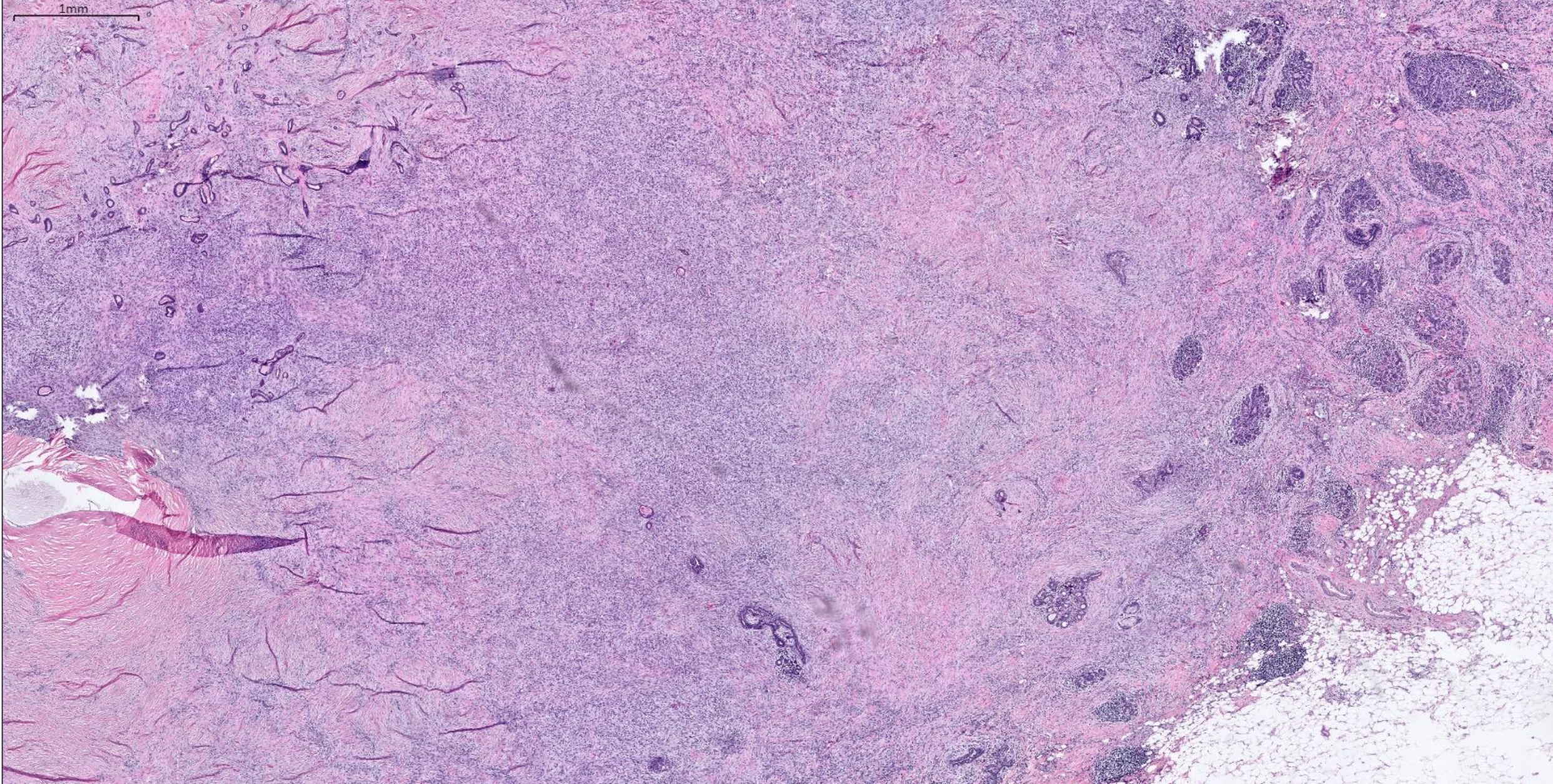
---

# CASE 3

---







# DIAGNOSTIC CONSIDERATIONS?

---