


The Case for Use of Social Media in Pathology

Silvija P. Gottesman, MD



Silvija P. Gottesman, MD

Assistant Professor of Dermatology & Pathology
Northwell Health - Long Island Jewish Medical Center
Lake Success, NY



DISCLOSURE

No relevant financial relationship or any conflicts of interest.

What is Social Media?



Ellen DeGeneres

@TheEllenShow

Follow

If only Bradley's arm was longer. Best photo ever. #oscars



7:06 PM - 2 Mar 2014


3,381,252 Retweets 2,378,7

221K 3.4M

3. Selena Gomez's kidney transplant donor



selenagomez



[View More on Instagram](#)



10,590,107 likes



doctor.silvi

doctor.silvi We are #engaged!!! Love you #fiance! @dubwell #engagement #couplephotos #toomushyforu #bklove #bushwick #photoshoot #brooklyn #newyorkcity

maryemdee Congrats!

pollisad Congratulations!!!!!!!

mdmac00 Congratulations!!!!

marija_pavlovska So srečka Silvi , samo ubavi raboti da ve pratat !



50 likes

OCTOBER 14, 2017

Add a comment...




@SGottesmanMD



mavericklifestylecr • Follow

mavericklifestylecr nothing beats a Costa



bronzekiosk • Follow

Bronze Kiosk

bronzekiosk Throwing it back to when we had these lush honeycomb 'crunchie' muffins 🍪 Our wonderful chefs make fresh and different muffins every morning! Make your Friday even better with a cup of @doubleroasters coffee and fresh housemade muffins #coffee #coffeelover #coffeeholic #coffeetime #cappuccino #sydneycafe #doubleroasters #muffins #muffinoftheday #latteart #chocolate #yummy #yum #foodporn



broomhousecoffeeshop and joannacubis like this

1 MINUTE AGO

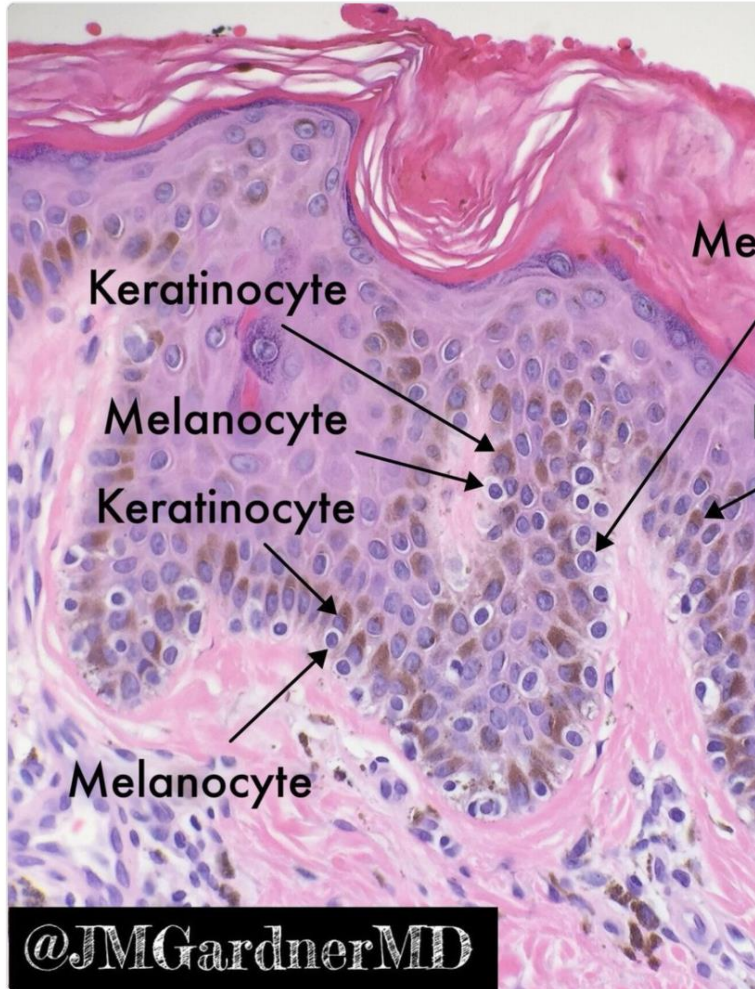
Add a comment... ⋮

Add a comment... ⋮



Jerad Gardner, MD
@JMGardnerMD

Lentiginous nevus. Perfect example of melanocytes (grey, not pigmented) and keratinocytes (lots of brown melanin).
#Pathology #dermpath #dermato



Half-Time Histology

SUPER BOWEL SUNDAY

The football-shaped egg of *Trichuris trichuria* wants to 'touchdown' in your colon

#histology #anatomy #pathology #SuperBowl #pathArt





Silvoja Gottesman MD
@SGottesmanMD

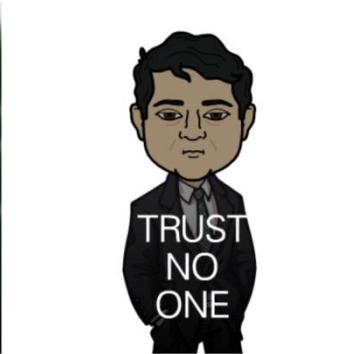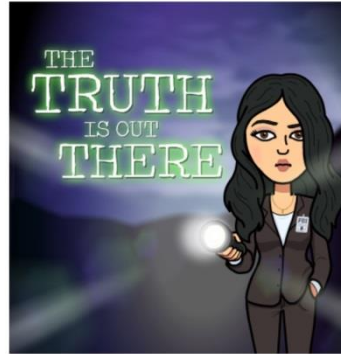Following

#Ackermaniacs take a selfie with Dr Ackerman. Painted by Dr @DiegoMoralesN.
Bonus pic: painting inspiration s
#mottirl #ASDP2017



Yasmine lahoubi Lys
@yasminelys

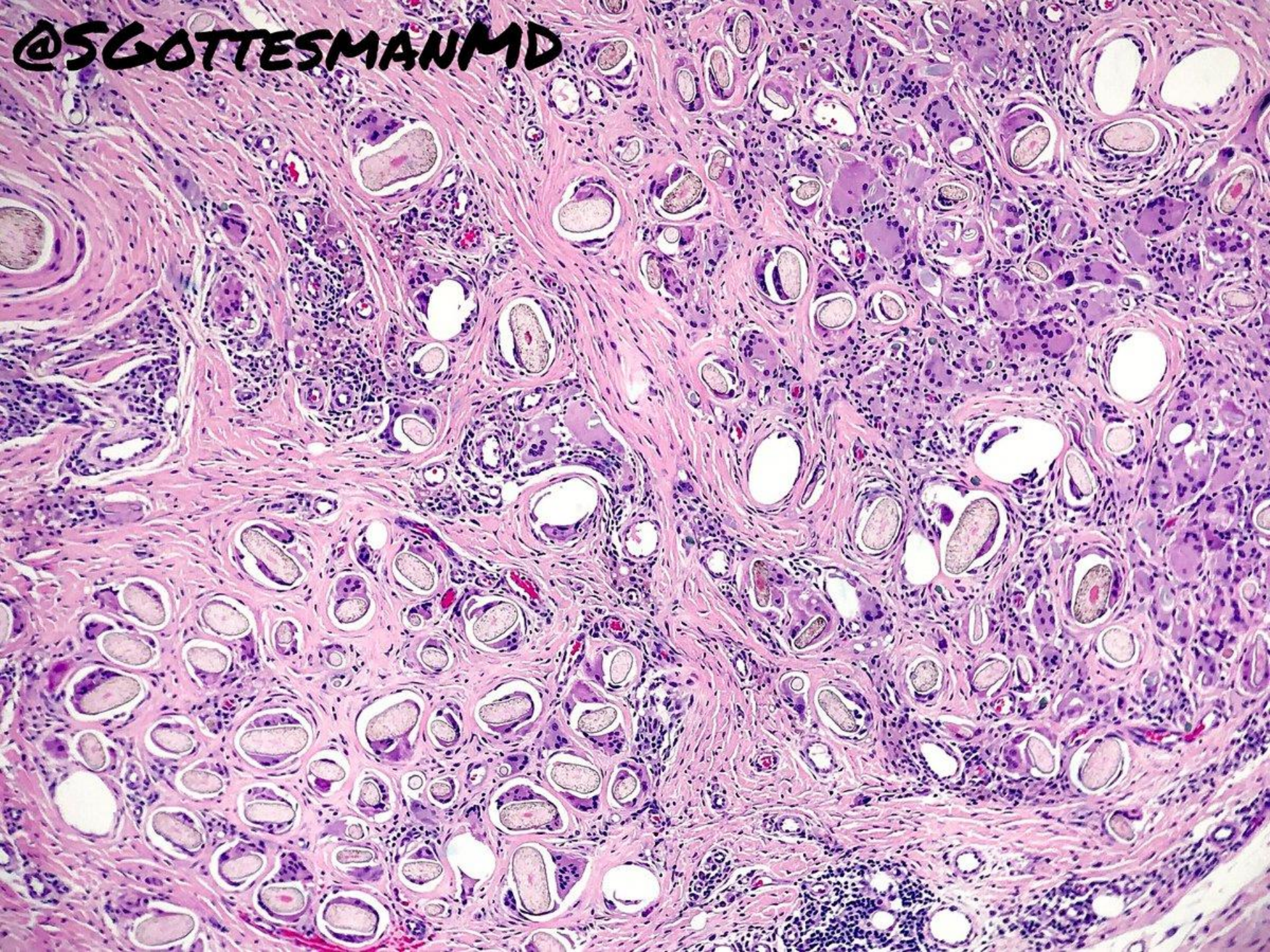
Following



ATION
SCA
FO
NE
NG
TS

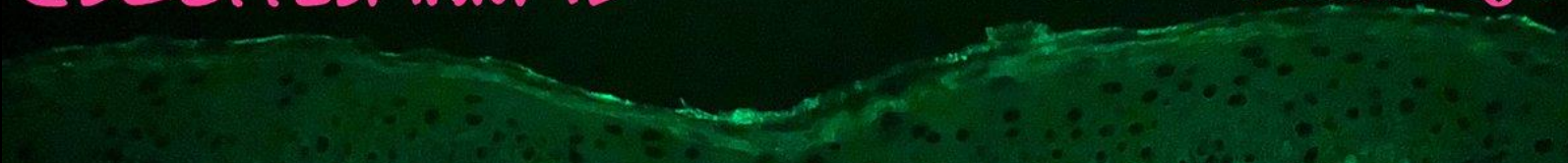
How do I use Twitter?

@SGOTTESMANMD



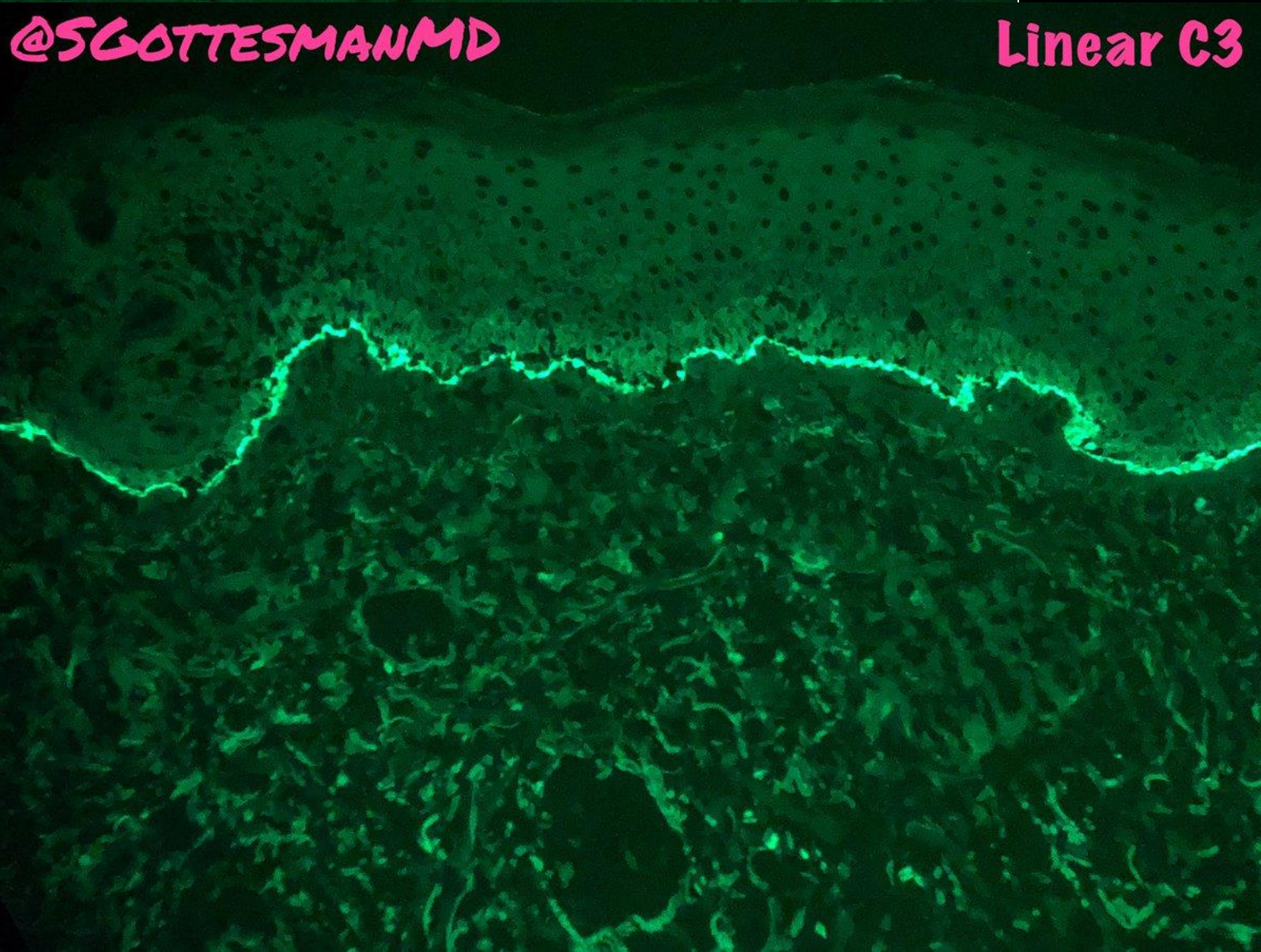
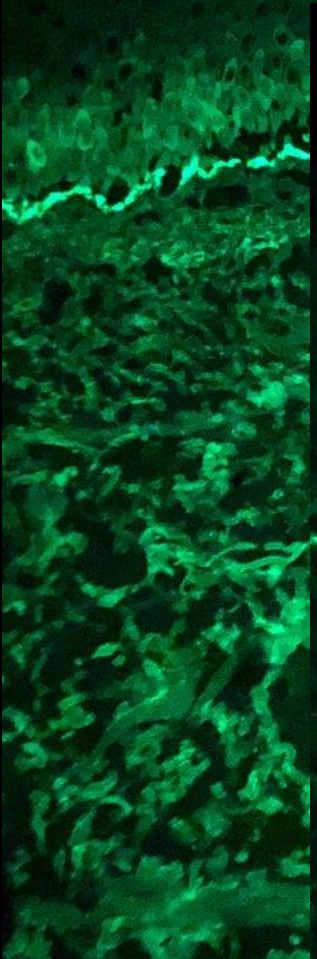
@SGOTTESMANMD

Linear IgG



@SGOTTESMANMD

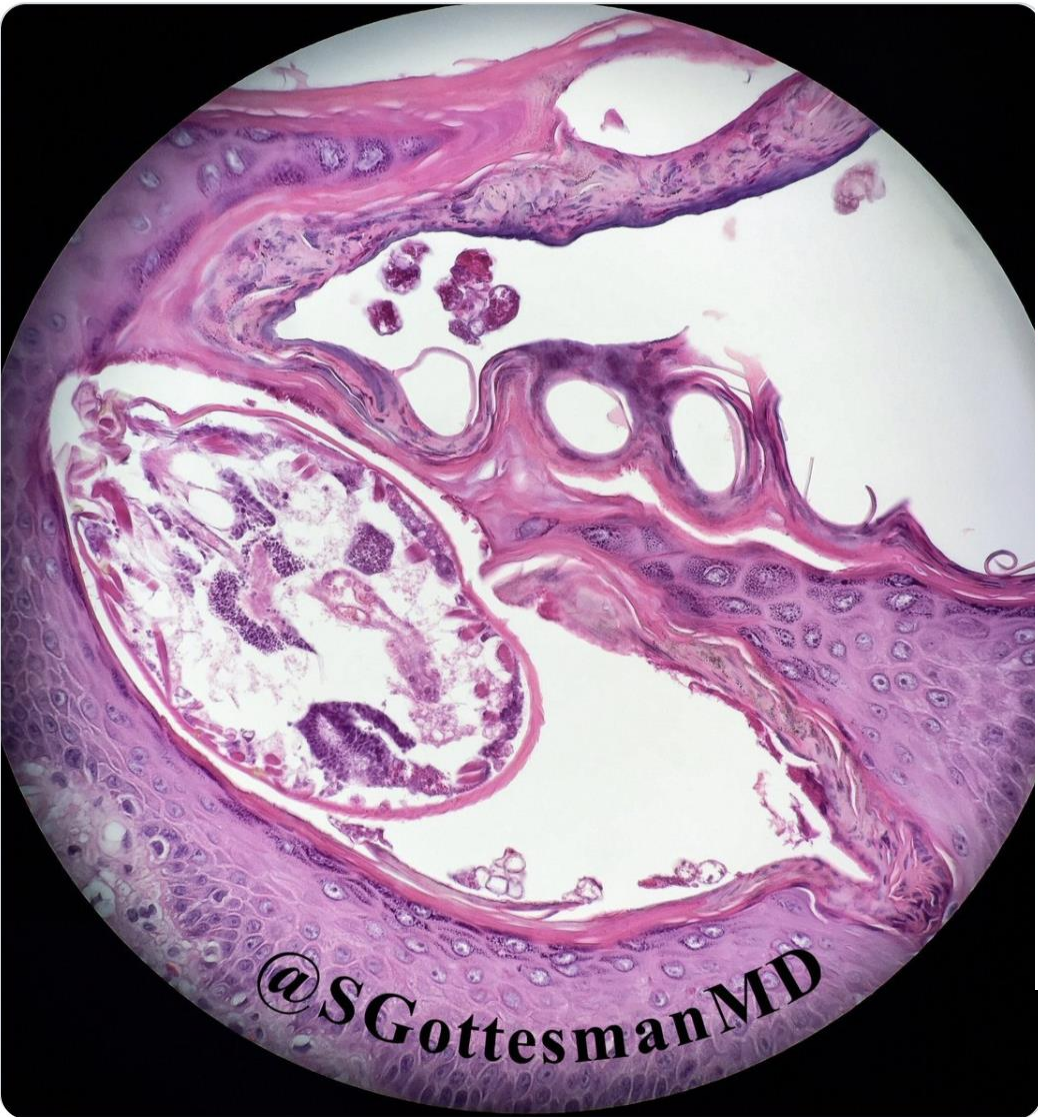
Linear C3





Silvija Gottesman MD
@SGottesmanMD

Patient in itch crisis. Think [#scabies](#)! 400x magnification.
[#ASDP2017](#) [#dermpath](#) [#dermatology](#) [#pathology](#)

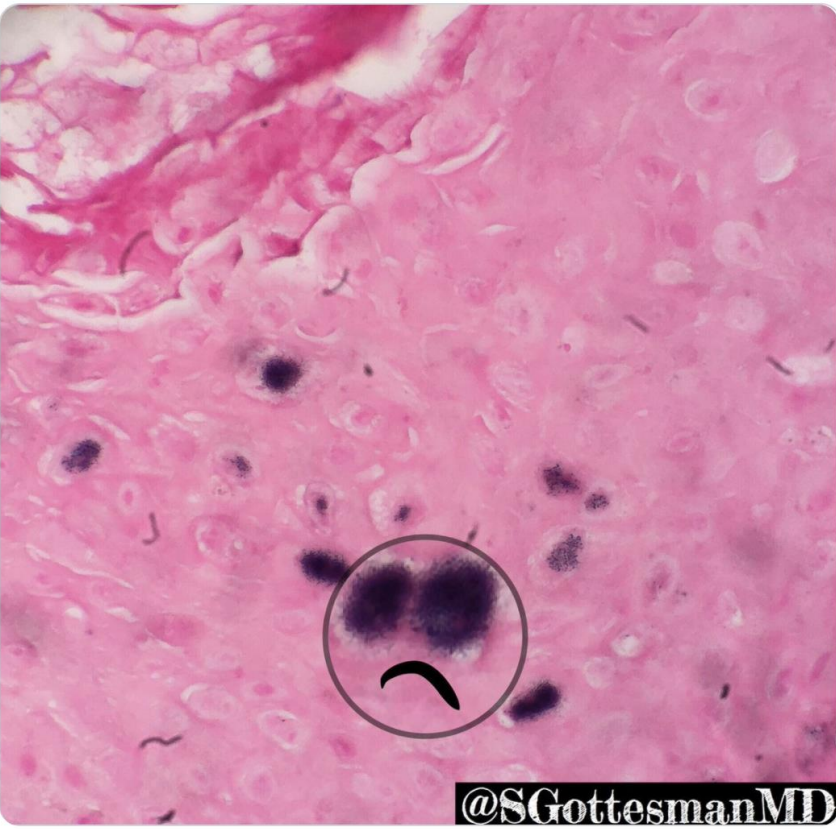

@SGottesmanMD



Silvija Gottesman MD
@SGottesmanMD

HPV, a hot topic here at the [#ASDP2017](#). In situ hybridization for HPV subtyping in [#condyloma](#). Example below was high risk (16,18) [#pathart](#)?



@SGottesmanMD

12:00 PM · Oct 27, 2017 from Baltimore, MD




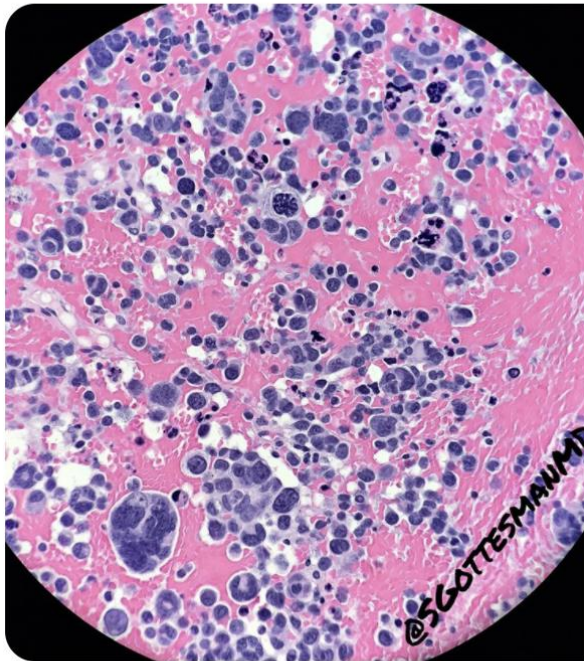
ottesmanMD



Silvija Gottesman MD
@SGottesmanMD



Mystery case. Let's get our grey cells to work. Tweet, Retweet and/or Comment. [#PoirotForever](#) [#Quiz](#) [#dermpath](#) [#dermatology](#) [#pathology](#) More pictures will be provided later...



#PoirotForever

Kalyani Bambal and 6 others

3:08 PM · Jan 1, 2018 from [Brooklyn, NY](#)

41 Retweets 70 Likes

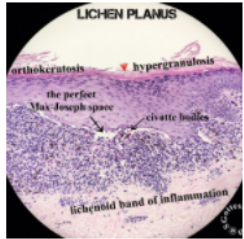


@SGottesmanMD

LICHEN PLANUS



Tweet Activity



Silvija Gottesman MD

@SGottesmanMD

Lichen Planus and the perfect Max-Joseph space. Numerous PAS+ civatte bodies present (apoptotic basal keratinocytes). Other features in photo below. [#dermpath](#) [#dermatology](#) [#pathology](#) [#education](#)
pic.twitter.com/wxQqunc2yo



Reach a bigger audience
Get more engagements by promoting this Tweet!

[Get started](#)

Impressions	24,024
Total engagements	1,668
Media engagements	787
Likes	275
Detail expands	236
Retweets	150
Profile clicks	150
Link clicks	28
Hashtag clicks	27
Replies	15

15

150

275



@SGottesmanMD

Hashtags



General & Miscellaneous:

#InSituPathologists – United States and Canadian Academy of Pathology (@TheUSCAP) annual meeting live tweet group
#pathology - general pathology hashtag
#pathologists - general pathology hashtag
#IamUSCAP - use for pathologist selfies at USCAP annual meeting
#PathBoards - pearls for pathology board exam studying
#PathResidents - pathology resident specific info
#pathArt - artistic or aesthetically beautiful pathology images

#IHCpath

#Grossognosis

#PathBugs

#ILookLikeAPathologist

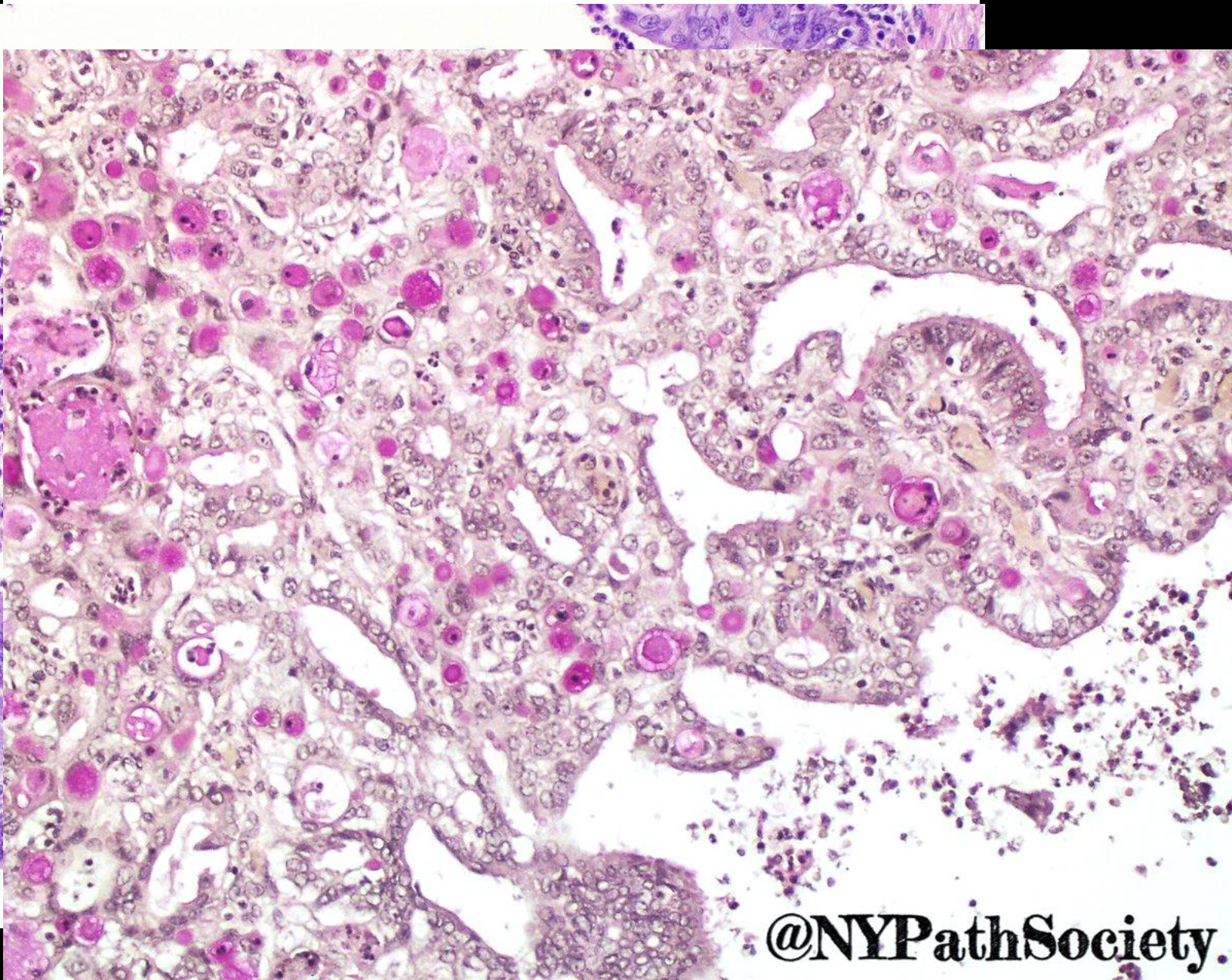
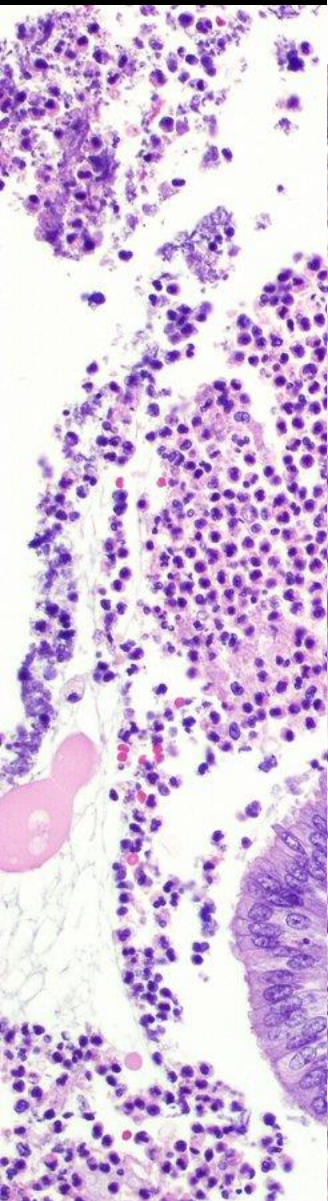
Pathology Subspecialty Specific

#Autopsy - autopsy pathology
#BloodBank - blood banking & transfusion medicine
#BreastPath - breast pathology
#BSTpath - bone and soft tissue pathology
#CardiacPath - cardiovascular pathology
#ClinPath - clinical pathology (general CP)
#Cytopath – cytopathology
#DermPath - dermatopathology
#EndoPath – endocrine pathology
#ENTPath - head and neck pathology
#EyePath - ophthalmic pathology
#FNAPath – fine needle aspirate (FNA) cytopathology
#ForensicPath – forensic pathology & forensics
#GIPath – gastrointestinal and liver pathology
#GUPath – genitourinary pathology
#Gynpath – gynecologic pathology
#HemePath - hematopathology
#pathInformatics – pathology informatics
#MolDx - molecular pathology
#NeuroPath - neuropathology
#PedsPath - pediatric pathology
#PulmPath – pulmonary and pleural pathology
#RenalPath - renal / medical kidney pathology
#SurgPath - surgical pathology



The NY Path Society

@NYPathSociety



@NYPathSociety

Chrome File Edit View History Bookmarks People Window Help

Secure <https://www.ncbi.nlm.nih.gov/pubmed>

NCBI Resources How To Sign in to NCBI

PubMed.gov
US National Library of Medicine
National Institutes of Health

PubMed "social media" and pathology Search

Create alert Advanced Help

Article types
Clinical Trial
Review
Customize ...

Text availability
Abstract
Free full text
Full text

Publication dates clear
5 years
10 years
✓ to 2008/12/31

Species
Humans
Other Animals

Clear all
Show additional filters

Search results
Items: 0

Filters activated: Publication date to 2008/12/31. [Clear all](#) to show 105 items.

Search details
"social media"[All Fields] AND ("pathology"[Subheading] OR "pathology"[All Fields] OR "pathology"[MeSH Terms]) AND ("0001/01/01"[PDAT] : "2008/12/31")

Search See more...

Recent Activity
Turn Off Clear

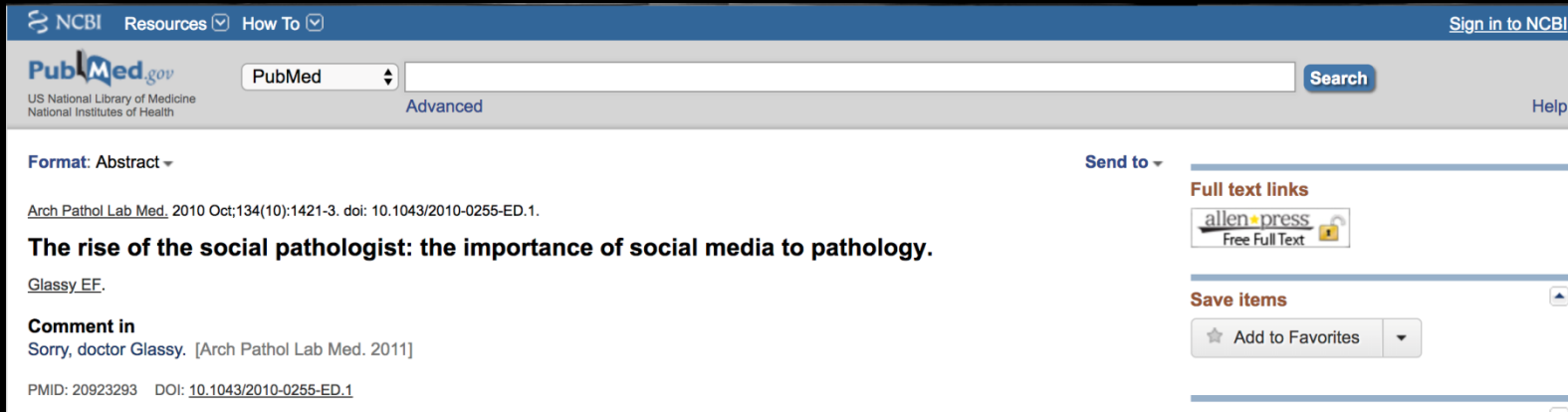
- "social media" AND and pathology AND ("0001/01/01"[PDat] : "2008... (0) PubMed
- "social media" AND and pathology AND ("1990/01/01"[PDat] : "2008... (0) PubMed
- "social media" AND and pathology AND ("1990/01/01"[PDat] : "1999... (0) PubMed
- The rise of the social pathologist: the importance of social media to patholog PubMed
- Should pathology get more social?: A growing movement touts the power of PubMed

See more...

You are here: NCBI > Literature > PubMed Support Center

GETTING STARTED	RESOURCES	POPULAR	FEATURED	NCBI INFORMATION
NCBI Education	Chemicals & Bioassays	PubMed	Genetic Testing Registry	About NCBI
NCBI Help Manual	Data & Software	Bookshelf	PubMed Health	Research at NCBI
NCBI Handbook	DNA & RNA	PubMed Central	GenBank	NCBI News & Blog
Training & Tutorials	Domains & Structures	PubMed Health	Reference Sequences	NCBI FTP Site

And then... it started



NCBI Resources How To Sign in to NCBI

PubMed.gov US National Library of Medicine National Institutes of Health

PubMed [Search] Advanced Help

Format: Abstract

Arch Pathol Lab Med. 2010 Oct;134(10):1421-3. doi: 10.1043/2010-0255-ED.1.

The rise of the social pathologist: the importance of social media to pathology.

Glassy EF.

Comment in
Sorry, doctor Glassy. [Arch Pathol Lab Med. 2011]

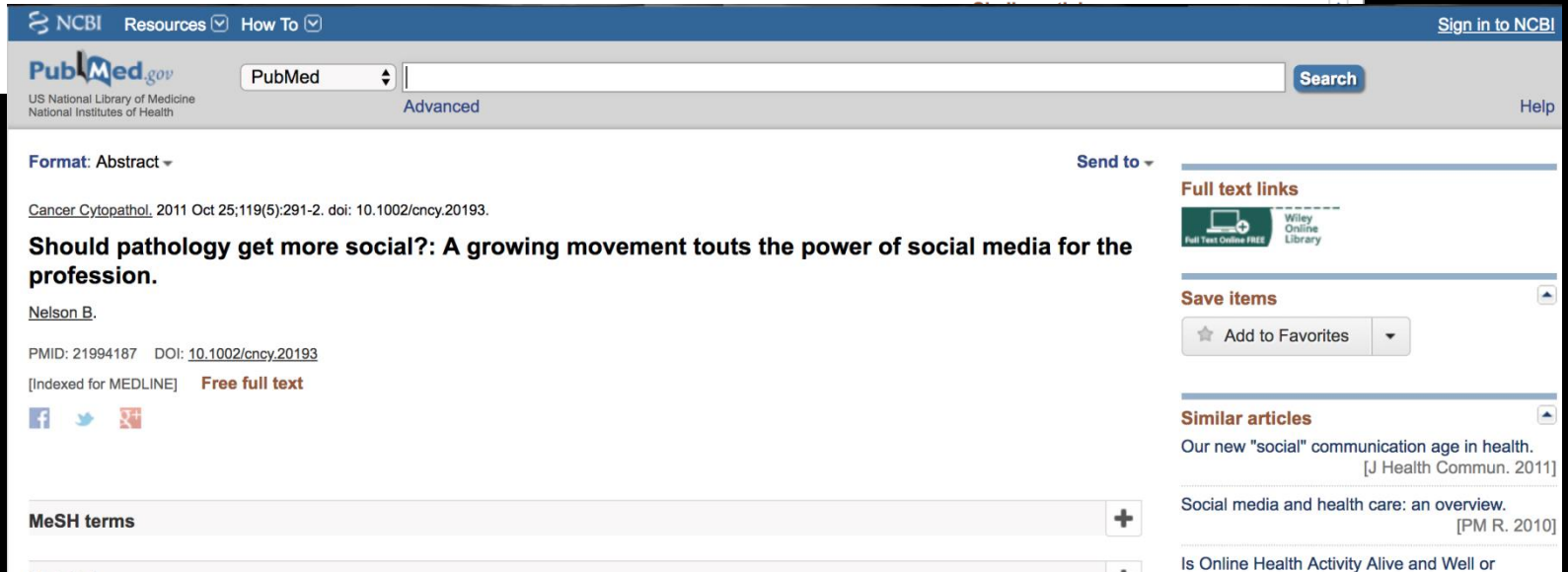
PMID: 20923293 DOI: 10.1043/2010-0255-ED.1

[Indexed for MEDLINE]

Send to

Full text links
allen+press Free Full Text

Save items
Add to Favorites



NCBI Resources How To Sign in to NCBI

PubMed.gov US National Library of Medicine National Institutes of Health

PubMed [Search] Advanced Help

Format: Abstract

Cancer Cytopathol. 2011 Oct 25;119(5):291-2. doi: 10.1002/ency.20193.

Should pathology get more social?: A growing movement touts the power of social media for the profession.

Nelson B.

PMID: 21994187 DOI: 10.1002/ency.20193

[Indexed for MEDLINE] Free full text

MeSH terms +

Send to

Full text links
Wiley Online Library Full Text Online FREE

Save items
Add to Favorites

Similar articles
Our new "social" communication age in health. [J Health Commun. 2011]
Social media and health care: an overview. [PM R. 2010]
Is Online Health Activity Alive and Well or

... and it hasn't stopped

NCBI Resources How To

PubMed.gov
US National Library of Medicine
National Institutes of Health

PubMed "social media" and pathology
Create RSS Create alert Advanced

Article types
Clinical Trial
Review
Customize ...

Text availability
Abstract
Free full text
Full text

Publication dates
5 years
10 years
✓ From 2008/01/01

Species
Humans
Other Animals

Clear all
Show additional filters

Format: Summary Sort by: Publication Date Per page: 20 Send to

Search results
Items: 1 to 20 of 105

<< First < Prev Page 1 of 6 Next > Last >>

1 Filters activated: Publication date from 2008/01/01. [Clear all](#) to show 105 items.

[#dermpathJC: The first online dermatopathology Twitter journal club.](#)

1. Gottesman SP, Klein WM, Hosler GA, Veprauskas KR, Rush PS, Gardner JM. J Cutan Pathol. 2018 May;45(5):370-373. doi: 10.1111/cup.13110. Epub 2018 Feb 26. No abstract available. PMID: 29369403 [Similar articles](#)

[Etiology of Sudden Cardiac Arrest and Death in US Competitive Athletes: A 2-Year Prospective Surveillance Study.](#)

2. Peterson DF, Siebert DM, Kucera KL, Thomas LC, Maleszewski JJ, Lopez-Anderson M, Suchsland MZ, Harmon KG, Drezner JA. Clin J Sport Med. 2018 Apr 9. doi: 10.1097/JSM.0000000000000598. [Epub ahead of print] PMID: 29634652 [Similar articles](#)


[Pathology and Professionalism in the Age of Social Media.](#)

3. Peedin AR, Karp JK. Arch Pathol Lab Med. 2018 Apr;142(4):441-442. doi: 10.5858/arpa.2017-0467-ED. Epub 2017 Dec 18. No abstract available. PMID: 29251997 [Similar articles](#)

[The Altmetric Attention Score: What Does It Mean and Why Should I Care?](#)

4. Elmore SA. Toxicol Pathol. 2018 Apr;46(3):252-255. doi: 10.1177/0192623318758294. Epub 2018 Feb 15. No abstract available. PMID: 29448902

The First Dermatopathology Twitter Journal Club



@DermpathJC

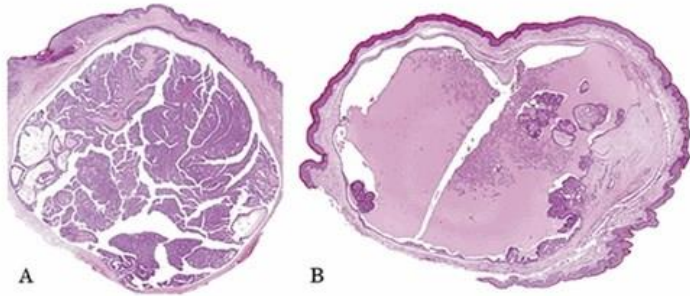
9PM EST

FOURTH THURSDAY OF EVERY MONTH




The American Journal of Dermatopathology

THE JOURNAL OF THE INTERNATIONAL SOCIETY OF DERMATOPATHOLOGY
Editor-in-Chief Omar P. Sangüeza, M.D.



 Wolters Kluwer

 www.amjdermatopathology.com

Volume 38 • Number 8 • August 2016

Full Text
OVID

JCP

JOURNAL OF
CUTANEOUS
PATHOLOGY

Wiley Online Library
www.wileyonlinelibrary.com



EDITOR-IN-CHIEF:
CHRISTOPHER R. SHEA
CHICAGO, IL, USA

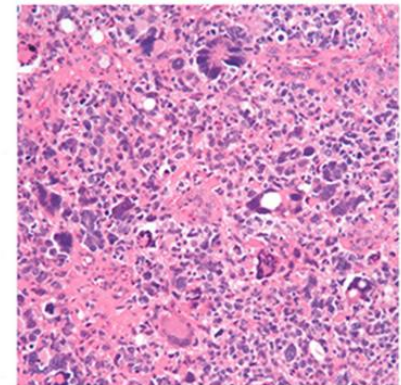
VOLUME 44
NO. 9
SEPTEMBER 2017

WILEY

OFFICIAL PUBLICATION OF

ARCHIVES

of Pathology & Laboratory Medicine



Presence of Isocitrate Dehydrogenase Mutation in Glioblastoma
Signifies Better Prognosis Compared to Other Glioblastomas

March 2017

Special Section—Contributions From
Emory University School of Medicine, Part I



DermPathJC
@DermPathJC

Save the date! #dermpathJC is on 8/24/2017, 9pm EST. Article PDF at tinyurl.com/BerEp4 Fun fact: the authors are active twitter users!

archivesofpathology.org

BerEp4, Cytokeratin 14, and Cytokeratin 17 Immunohistochemical Staining Aid in Differentiation of Basaloid Squamous Cell Carcinoma From Basal Cell Carcinoma With Squamous Metaplasia

Katy R. Linskey, MD; Devon C. Gimbel, MD; Lawrence R. Zukerberg, MD; Lynn M. Duncan, MD; Peter M. Sadow, MD, PhD; Rosalynn M. Nazarian, MD

Context.—Basaloid squamous cell carcinoma (bSCC) is an uncommon variant of squamous cell carcinoma, which may overlap histologically with basal cell carcinoma with squamous metaplasia (BCCm).
Objective.—To aid in the differentiation of these neoplasms using immunohistochemical staining because of the worse prognosis associated with bSCC.
Design.—Using immunohistochemical techniques, we investigated BerEp4, cytokeratin 17 (CK17), and cytokeratin 14 (CK14) protein expression in 25 cases of bSCC (8 cutaneous [32%], 12 aerodigestive tract [48%]), and 5 lymph node metastases (20%) and 43 cases of BCCm (39 cutaneous [91%], and 4 metastases [9%]). An immunoreactivity score was assigned using the percentage of tumor cells staining and the pattern of expression. Interobserver agreement for 2 independent pathologists was assessed using a κ coefficient.
Results.—The mean percentage of staining was significantly higher in BCCm, compared with bSCC (BerEp4, $P = .006$; CK17, $P < .001$; CK14, $P < .001$; unpaired t test), with 58% of BCCm cases (25 of 43) displaying diffuse staining for all markers, and nearly all (98%; 42 of 43) displaying diffuse staining for CK17 and CK14. In contrast, no bSCC cases (0%) displayed diffuse staining for all 3 markers, and only 8% (2 of 25) displayed diffuse staining for CK17 and CK14. High interobserver agreement was determined.
Conclusions.—BerEp4 alone is unreliable for differentiation between BCCm and bSCC, and the addition of either CK14 or CK17 will augment the sensitivity and negative predictive value of BerEp4 staining in BCCm and bSCC diagnosis. (*Arch Pathol Lab Med*, 2013;137:1591-1598; doi: 10.5858/arpa.2012-0424-OA)

9:34 PM - 4 Aug 2017

46 Retweets 73 Likes

Silvija Gottesman MD, Jerad Gardner, MD, Katy Veprauskas and 7 others

4 46 73



DermPathJC
@DermPathJC

Clinicopathologic and genetic findings of desmoplastic melanoma, MPNST, and cutaneous clear cell sarcoma #dermpathJC #dermpath

MACHADO ET AL.

WILEY | JCP | 637

TABLE 1 Differential diagnosis of the most challenging cutaneous S100-positive spindle cell lesions

	Desmoplastic/spindle cell melanoma	Superficial malignant peripheral nerve sheath tumor	Cutaneous clear cell sarcoma
Age	Elderly patients	20-50 y	Young to middle-aged patients
Anatomical location	Sun-exposed skin of the head and neck, near mucous membrane, volar skin	Proximal upper and lower extremities and trunk, relationship with a major nerve or with a neural benign lesion	Lower limbs
Architectural pattern	Spindle cell pattern, amelanotic or melanotic, +/- desmoplasia	Spindle and/or epithelioid pattern, amelanotic	Spindle cell tumor with fascicles and nests, surrounded by fibrous connective bands and scattered weath-like giant cells
Epidermis	80% Lentigo maligna	Lentigo maligna absent	Lentigo maligna absent
Dermis	Frequent solar elastosis	Solar elastosis +/-	No solar elastosis
S-100	+++ diffuse (almost all)	+ Focal (<50%) in spindle cell variant, ++ + in the epithelioid variant	++, not uniformly expressed
Melan-A	-/+	-	++, not uniformly expressed
HMB-45	-/+	-	++, not uniformly expressed
SOX-10	+ (almost all)	+75%	-/+
MITF-1	-	-	+/-
p75	+95%	+	+
HSK27me3	Positive	Loss of expression >50% of tumors	Positive
BRAF	+30% BRAF (spindle)/5% desmoplastic**	-/+	WT
NRAS	WT	WT	WT
NF1	Mutation	Mutation	WT
EWSR1	No rearrangement	No rearrangement	Rearrangement

6:34 PM - 28 Sep 2017

43 Retweets 50 Likes

4 43 50



DermPathJC
@DermPathJC

Usual staining pattern of CK10, Ki67 and p16 in pagetoid Bowen's disease. Might I say excellent images! #dermpathjc

Kalegadda and Bier-Auer

Am J Dermatopathol • Volume 39, Number 6, June 2017

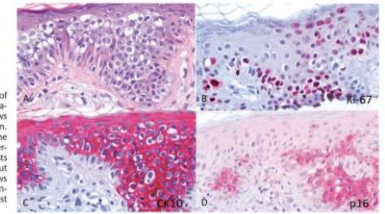


FIGURE 3. Usual staining pattern of CK10, Ki67, and p16 in PBD: Hematoxylin and eosin $\times 400$ (A) shows crowding and nuclear pleomorphism. Ki67 shows many positive cells, some located in the upper third of epidermis (B). CK10 is expressed in the nests and the surrounding epithelium, but sparing the basal cells (C). p16 shows strong nuclear and cytoplasmic staining in more than 75% of the nest cells, pattern 1 (D).

6:43 PM - 27 Jul 2017

26 Retweets 26 Likes

4 26 26



Tweet your reply

#dermpathJC



Walter Klein MD
@WMKleinMD

Following

My takeaway with this article is BCC is SOX10 negative and many adnexal tumors are positive [#dermpathjc](#)

6:05 PM - 29 Jun 2017

9 Retweets 21 Likes



5 9 21



Tweet your reply



Vijay Shankar S @VijayPatho · Jun 29

Replying to @WMKleinMD

Follicular tumors vs BCC would have been interesting [#dermpathjc](#)

2 2 6



Annie O. Morrison MD @AnnieMorrisonMD · Jun 29

Yes! Which one of the new [#dermpath](#) fellows starting on Monday want's to take this on? [#dermpathJC](#)

1 1 2



Walter Klein MD @WMKleinMD · Jun 29

I think SOX10 would be negative in all follicular tumors [#dermpathjc](#)

3 2 6



James A. Ramirez @JRamirezMD · Jun 29

I thought the same for apocrine 😊 [#dermpathjc](#)

#dermpathJC

Top Latest People Photos



Belinda Lategan @belinda_lategan · Jun 29

Yes neg in BCC can be helpful in ddx of other lesions? #dermpathjc

1 2 3



Vijay Shankar S @VijayPatho · Jun 29

Yes, particularly small, poorly oriented biopsy, where the diagnosis is challenging, as the study mentions#dermpathjc

1



Annie O. Morrison MD @AnnieMorrisonMD · Jun 29

Replying to @WMKleinMD

I am tending toward agreeing with @WMKleinMD #dermpathJC

1 1 5



Joseph Susa, DO @CutisViaLux · Jun 29

Same here. Did not really convince me to use #Sox10 for adnexal neoplasms. Maybe in rare circumstance when adnexal v bcc.

2 3 7



Mariantonieta Tirado @tonitatirado · Jun 29

It didn't convince me either for adnexal tu #dermpathjc

1 1 4



Mariantonieta Tirado @tonitatirado · Jun 29

Interesting that stains mammary gland (apocrine) but not skin apocrine glands. Does seem to be distinguishing between apo & ecc #dermpathjc

2 3 7



Belinda Lategan @belinda_lategan · Jun 29

Definitely something to remember if you have a lesion in the breast/skin of breast #dermpathjc

1 4 6



Annie O. Morrison MD @AnnieMorrisonMD · Jun 29

I wonder if primary cutaneous Adenoid CysticCa stains differently than

#dermpathJC

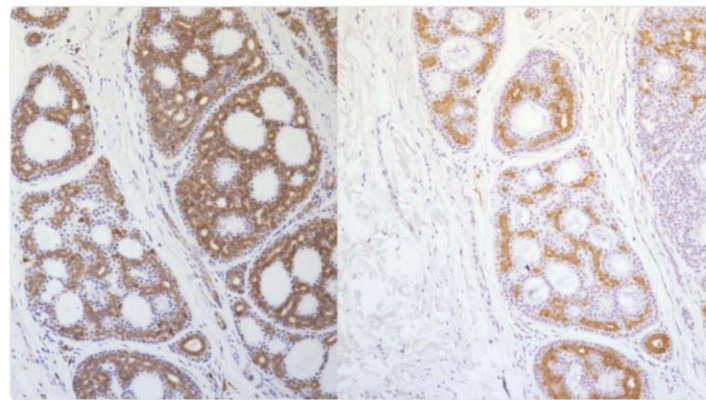


Annie O. Morrison MD @AnnieMorrisonMD · Jun 29
I wonder if primary cutaneous Adenoid CysticCa stains differently than salivary/breast/pulmonary ACC? #dermpathJC #dermpath #ENTpath

4 3 7



Jerad Gardner, MD @JMGardnerMD · Jun 29
We didn't try sox-10 for our cutaneous adenoid cystic report. Ours had CD117 (L) & focal p16 (R). ncbi.nlm.nih.gov/m/pubmed/25062... #dermpathjc



5 7



James A. Ramirez @JRamirezMD · Jun 29
Replying to @WMKleinMD
Agree. And adnexal tumor derivation is bewildering!

1 2



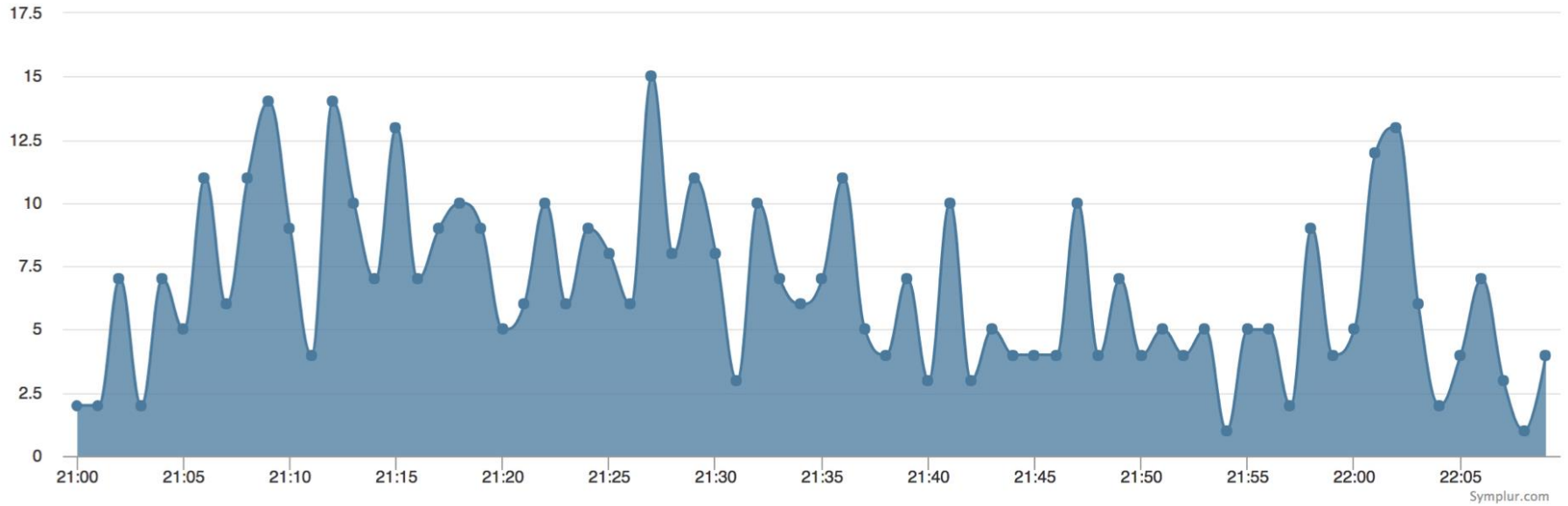
Patrick Rush @DrPatrickRush · Jun 29
Replying to @WMKleinMD
Ditto

1




docvaruna @docvaruna · Jun 29

Tweet Activity on #dermpathJC



#dermpathJC Participants



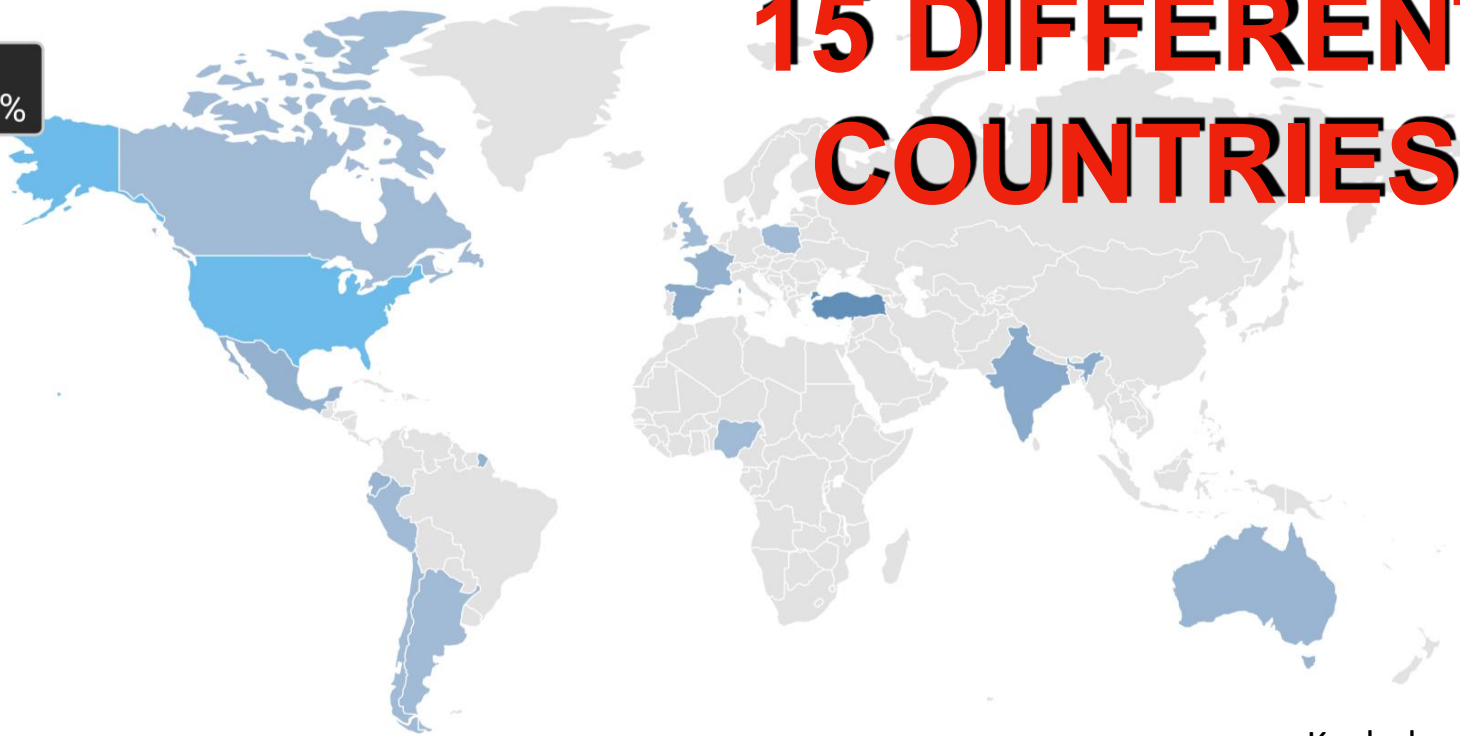
3,891 #dermpathJC TWEETS

**7.37 MILLION
IMPRESSIONS**

189 PARTICIPANTS

United States
Percentage: 65.00%

15 DIFFERENT COUNTRIES





Tweets **2,628** Following **3,924** Followers **3,812** Likes **725**

Following

Pathology JC

@path_JC Follows you

Online Pathology Journal Club #pathJC
#pathology #JournalClub

pathjc.wordpress.com

Joined June 2016

Born on June 20

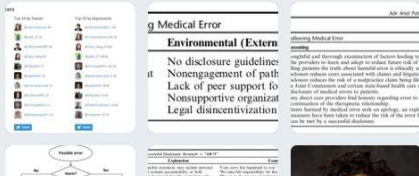Tweet to

Message

745 Followers you know



97 Photos and videos



Tweets Tweets & replies Media

Pinned Tweet



Pathology JC @path_JC · Apr 9
Join us for April #PathJC on Error Disclosure!

April 17: 9 pm EST

April 18: 9 pm CET (4 pm EST)

Moderated by @yaelheher @Sara_Jiang

THANK YOU to Advances in Anatomic Pathology EIC @MahulAmin and @WKHealth for supporting open access to the article:
ncbi.nlm.nih.gov/pubmed/29356714





The New York Pathological Society

Organized in 1844 Incorporated in 1886



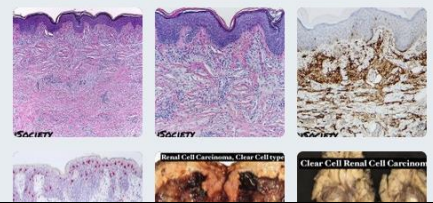
Tweets **173** Following **1,162** Followers **867** Likes **104** Lists **3** Moments **0** [Edit profile](#)

The NY Path Society

@NYPathSociety

The official Twitter account of the New York Pathological Society. [#NYPathSoc](#) [#NYPathQuiz](#) [#pathology](#) [#pathologists](#) [#pathboards](#) [#IHCpath](#)

New York, NY
[nypathsociety.org](#)
 Joined October 2015
 49 Photos and videos



Tweets Tweets & replies Media

Pinned Tweet



The NY Path Society @NYPathSociety · Apr 1
[#NYPathSociety](#) [#Pathology](#) [#Pathologists](#) The New York Pathological Society will host its annual President's Symposium on May 5, 2018. For more information:



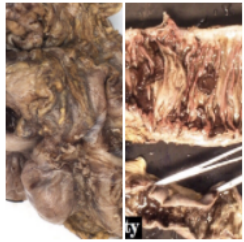
The NY Path Society

@NYPathSociety



Tweet one, tweet all. Time for

Tweet Activity



The NY Path Society

@NYPathSociety

Tweet one, tweet all. Time for **#grossognosis!** Guess the organ, name the findings and yes the DDX! Slides to follow. **#NYPathQuiz** **#pathology** **#pathologists** pic.twitter.com/IYYUtQWbyg

Impressions	6,776
Total engagements	715
Media engagements	380
Detail expands	132
Profile clicks	49
Likes	48
Hashtag clicks	33
Link clicks	31
Retweets	28
Replies	13
Follows	1



Reach a bigger audience

Get more engagements by promoting this Tweet!

Get started

28 Retweets **48 Likes**



👤 Vijay Shankar S, Raavi Gupta, Karen Pinto DNB, FRCPath and 7 others

💬 13

↻ 28

❤️ 48



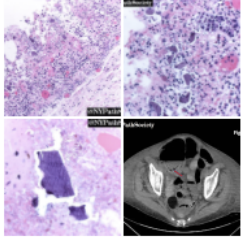


The NY Path Society

@NYPathSociety



Tweet Activity



The NY Path Society

@NYPathSociety

Thank you so much for participating in our **#grossognosis #NYPathQuiz** debut. The answer: bowel ischemia 2/2 Kayexalate induced colitis. Pneumatosis of the bowel (CT image). Read more at <https://nypathsociety.org/case-of-the-week/case5> Case submitted by **@YonahZiambaMD** & Dr Arvind Rishi **#pathology #Gpath** <pic.twitter.com/iXTvzFJHiH>

Impressions	6,153
Total engagements	420
Media engagements	179
Detail expands	71
Likes	54
Retweets	43
Profile clicks	35
Link clicks	24
Replies	7
Hashtag clicks	6
Follows	1



Reach a bigger audience

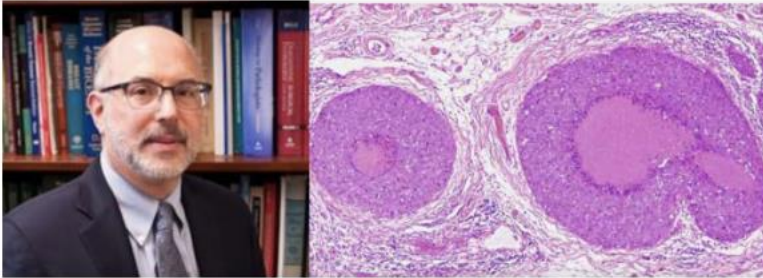
Get more engagements by promoting this Tweet!

Get started

5:28 PM - 30 Mar 2018

43 Retweets 54 Likes





The Continuing Dilemma of Ductal Carcinoma in situ

NY Pathological Society Thursday,
February 8, 2018 131 E 76th Street,
Einhorn Auditorium of Lenox Hill
Hospital 6 pm – Lecture: The Continuing
Dilemma of [...]

A 69 year old woman on chemotherapy

Professors, Doctors and other
Specialist in the NYPS Community

JOIN

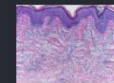
gical

ts in
4 and
ournal
cal
1955.

Recent Articles

President's Symposium Handouts

🕒 May 3, 2018



**Focus on Cellular
Neurothekeoma and
its Fibrohistiocytic
Origin**

🕒 April 30, 2018

Quick
Links

- Contact Us
- Register
- Login
- Profile
- Account Settings
- Community
- Careers

Social Media Presence

- Website: <https://nypathsociety.org/>
- Twitter: @NYPathSociety
- Instagram: newyorkpathsociety
- Facebook: New York Pathological Society

Contact: Silvija Gottesman, MD

Social Media Committee Chair

silvija.gottesman@gmail.com

To be featured on our social media pages, please submit H&E/IHC/etc images with 1-2 sentences describing the patient scenario.

Case of the Week

Website: <https://nypathsociety.org/category/case-of-the-week>

Arvind Rishi, MD

Editor, Case of the Week Series

arishi@northwell.edu

Yonah Ziemba, MD

Resident Coordinator, Case of the Week Series

yziemba@northwell.edu

Instructions: Features an interesting case. Submission requires 1-2 paragraphs of text and 1-2 references.

Don't Forget

More information available at our website:

<https://nypathsociety.org/>

Our conference hashtag is **#NYPathSoc**

Tweet, Retweet, Learn

THANK

YOU!

@SGottesmanMD